

**Selenia[®] Dimensions[®] and 3Dimensions[™] Breast
Tomosynthesis Physician Labeling**

1.1 Manufacturer Contact Information

Hologic, Inc.
36 Apple Ridge Road
Danbury, CT
06810 USA
1-800-447-1856
Technical Support:
1-877-371-4372

1.2 Prescription Use Statement

 Only United States federal law restricts this device to use by, or on the order of, a physician.

1.3 Intended Use

1.3.1 Selenia Dimensions

The Hologic® Selenia® Dimensions® system generates digital mammographic images that can be used for screening and diagnosis of breast cancer. The Selenia Dimensions (2D or 3D) system is intended for use in the same clinical applications as a 2D mammography system for screening mammograms. Specifically, the Selenia Dimensions system can be used to generate 2D digital mammograms and 3D mammograms. Each screening examination may consist of:

- a 2D FFDM image set, or
- a 2D and 3D image set, where the 2D image can be either a FFDM or a 2D image generated from the 3D image set

The Selenia Dimensions system may also be used for additional diagnostic workup of the breast.



Note

In Canada and Singapore, Tomosynthesis is not approved for screening, and must be used in conjunction with a 2D image (either a FFDM image or 2D image generated from the 3D image set).

1.3.2 3Dimensions

Rx Only Caution: Federal law restricts this device to sale by or on the order of a physician.

The Hologic® 3Dimensions™ system is indicated to generate digital mammographic images that can be used for screening and diagnosis of breast cancer. The 3Dimensions (2D or 3D) system is intended for use in the same clinical applications as a 2D mammography system for screening mammograms. Specifically, the 3Dimensions system can be used to generate 2D digital mammograms and 3D mammograms. Each screening examination may consist of:

- a 2D FFDM image set
- - OR -
- a 2D and 3D image set, where the 2D image can be either an FFDM or a 2D image generated from the 3D image set

The 3Dimensions system may also be used for additional diagnostic workup of the breast.



Note

In Canada and Singapore, Tomosynthesis is not approved for screening, and must be used in conjunction with a 2D image (either a FFDM image or 2D image generated from the 3D image set).

1.4 Definition of Hologic Tomosynthesis Product

Standard Resolution Tomosynthesis: A licensed Hologic feature enabling a standard resolution breast tomosynthesis (BT) scan. The standard resolution tomosynthesis image has a pixel resolution of approximately 100 microns.

Clarity HD High-resolution Tomosynthesis: A licensed Hologic feature enabling a high resolution breast tomosynthesis (BT) scan. The high resolution tomosynthesis image has a pixel resolution of 70 microns.

1.5 Potential Adverse Effects of Mammography Systems on Health

Below is a list of the potential adverse effects (such as complications) associated with the use of the device (these risks are the same as for other screen-film or digital mammography systems):

- Excessive breast compression
- Excessive x-ray exposure
- Electric shock
- Infection
- Skin irritation, abrasions, or puncture wounds

No serious adverse events were reported for the patients enrolled in the clinical study.

1.6 Major Warnings / Cautions / Contraindications



Note

Refer to the *User Guide* for more information about warnings and precautions.

1.6.1 Warnings



WARNING!

Risk of electric shock. Only connect this equipment to supply mains with Protective Earth.



WARNING!

For North American electrical safety requirements, use a Hospital Grade receptacle to supply a correct Ground.



WARNING!

Electrical equipment used near flammable anesthetics can cause an explosion.



WARNING!

To correctly isolate the system, attach only approved accessories or options to the system. Only approved personnel can change the connections.



WARNING!

Keep a 1.5 meter safe distance between the patient and any non-patient devices.

Do not install non-patient system components (like the Workflow Manager, a diagnostic review workstation, or a hard copy printer) in the Patient Area.



Warning:

C-arm movement is motorized.



Warning:

You increase the patient dose to high levels when you increase the AEC exposure adjustment. You increase the image noise or decrease image quality when you decrease the AEC exposure adjustment.



Warning:

Control the access to the equipment according to local regulations for radiation protection.



Warning:

To prevent a higher radiation dose to the patient, only put approved materials in the x-ray beam path.



Warning:

This system can be dangerous to the patient and the user. Always follow the safety precautions for x-ray exposures.



Warning:

Risk of entrapment. Make sure that the C-arm has 50 cm (20 inches) of clearance to any object during C-arm rotation. Do not use Auto Rotation when C-arm clearance is less than 50 cm (20 inches).

1.6.2 Cautions



Caution:

The system is a medical device and not a normal computer. Only make approved changes to the hardware or software. Install this device behind a firewall for network security. The computer virus protection or network security for this medical device is not supplied (for example, a computer firewall). The network security and anti-virus provisions are the responsibility of the user.

1.6.3 Contraindications

There are no known contraindications.

1.7 Clinical Studies Summary - Standard Resolution Tomosynthesis

Hologic compared the performance of 2D plus 3D breast imaging to conventional (2D) imaging in two reader studies with different readers. Reader Study 1 and Reader Study 2 included 312 and 310 cases which were enriched with 48 and 51 cancer cases, respectively. The study cases included images from women with both fatty and dense breasts. These reader studies were designed to evaluate the use of 2D plus 3D imaging in a screening mode in place of conventional 2D screening.

The first reader study (Reader Study 1) was designed to demonstrate that the area under the Receiver Operating Characteristic (ROC) curve for 2D plus 3D was statistically significantly superior to the area under the ROC curve for 2D alone. It was also designed to demonstrate that a significant reduction in recall rate of non-cancer cases could be obtained. In Reader Study 1, using 12 trained radiologists, these endpoints were achieved.

A second reader study (Reader Study 2), using 15 radiologists who did not participate in Reader Study 1, was carried out to investigate the impact of using only the 3D MLO view of the breast instead of both the 3D CC and 3D MLO views. In Reader Study 2, the performance of 3 separate arms was compared: (1) 2D; (2) 2D plus 3D; (3) 2D plus 3D MLO. Arm 1 and Arm 2 were the same in Reader Study 1 and 2, whereas Arm 3 in Reader Study 2 was the new arm with only one 3D view – the MLO. Another difference in Study 2 was that the locations and the types of the lesions recalled by the readers were also recorded to investigate an observation from Reader Study 1. This information was not recorded in the first reader study. ROC and non-cancer recall rate reduction were also the endpoints for Reader Study 2. The outcome for Arm 1 and Arm 2 of Reader Study 2 was almost identical ROC curves for 2D plus 3D and 2D alone as were obtained in Reader Study 1. The study endpoints of Reader Study 2 were achieved. The new Arm 3 of Reader Study 2 had an ROC curve lying midway between the 2D and the 2D plus 3D ROC curves. Statistically significant reduction in non-cancer recall rate was demonstrated in Reader Study 2. Again, all study endpoints were met in Reader Study 2.

In both reader studies, there was an inherent inclusion bias against 3D with respect to cancer detection in a screening population. Nearly all of the cancers included in the reader studies had been detected on 2D images as part of the standard 2D screening workups. This is a bias against 3D imaging because those cancers that may have been detected using 3D imaging are not included and it is not possible to measure the actual gain in sensitivity (cancer detection) that would occur in clinical practice. In Hologic's reader study case sets where the cancers have been detected using 2D imaging it is not realistic to find improved cancer detection (sensitivity) using 2D plus 3D compared to 2D alone. In a clinical screening setting, given the superior ROC performance demonstrated in Hologic's clinical studies, it would be expected that 2D plus 3D would increase cancer detection.

The pooled ROC curves for Reader Study 1 are shown in Figure 1. The pooled ROC curves for both Reader Study 1 and Reader Study 2 are shown in Figure 2. 2D plus 3D has a superior ROC curve compared to 2D alone in both studies. A superior ROC curve

is one that is closer to the upper left of the axes. A perfect imaging method would have a true positive fraction of 1 (100%) and a false positive fraction of 0 (0%). These curves also allow estimation of the potential gains in sensitivity and specificity that may be achieved by using 2D plus 3D compared to 2D alone and these gains are discussed in the risk benefit section.

Reader Study 2 also measured the ROC performance of 2D plus 3D MLO. The estimated clinical benefit based on the ROC curves of adding just MLO 3D images is shown in Figure 2 and is approximately one half of the benefit that may be achieved from adding both the MLO and CC 3D images. Therefore the use of 2D plus 3D (MLO and CC) provides the largest clinical benefit allowing for larger potential gains in both sensitivity (cancer detection) and specificity (recall rate).

The pooled ROC results for primary comparison of 2D versus 2D plus 3D along with the studies' operating points (cancer recall rate and non-cancer recall rate) are shown in Figure 3. The ROC curves for the two studies are almost identical, and the operating points are located on the ROC curves. Based on the readers' differential adherence to their training for Reader Study 1 and Reader Study 2, the operating points "move" along the ROC curve. This is the result expected according to ROC methodology when different recall thresholds are used to read mammograms based on different radiologists' approach to interpretation. In both reader studies the statistically superior ROC area for 2D plus 3D imaging compared to 2D imaging is the primary clinical study result which demonstrates the superiority of 2D plus 3D imaging compared to 2D imaging alone.

Figure 1: Pooled ROC curves for all Readers; Reader Study 1

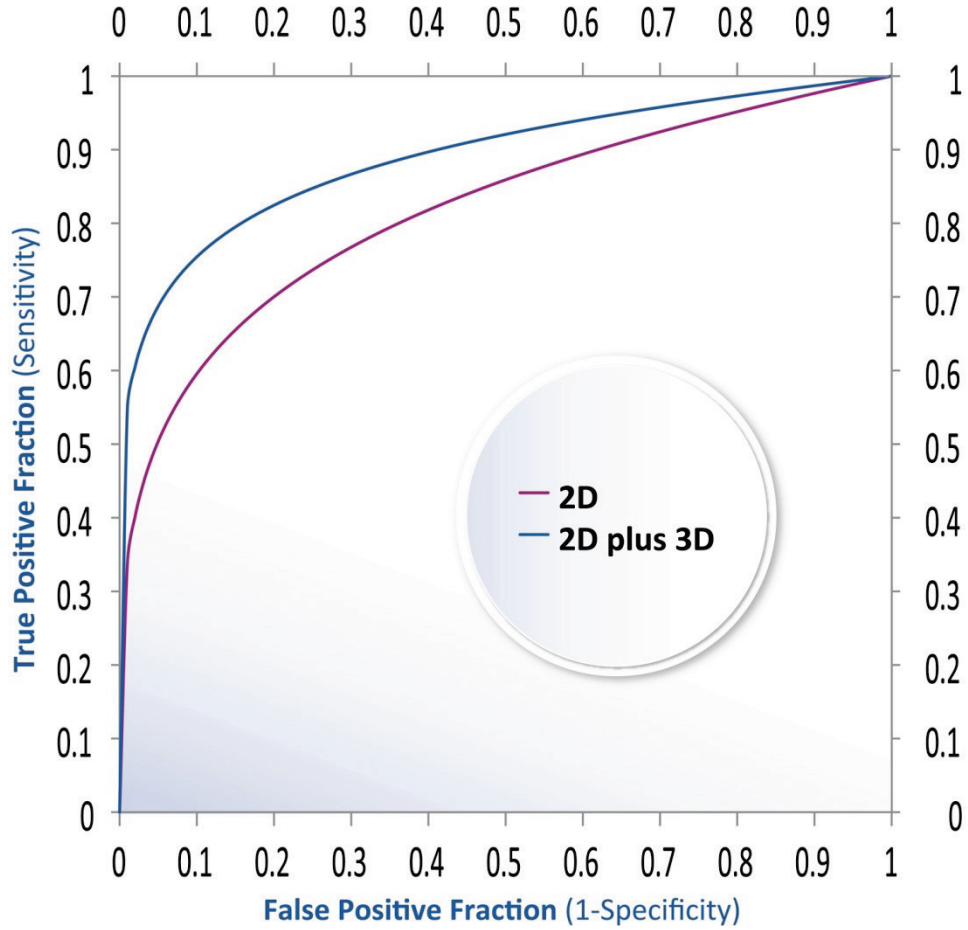


Figure 2: Pooled ROC curves for all Readers; Reader Study 1 and Reader Study 2

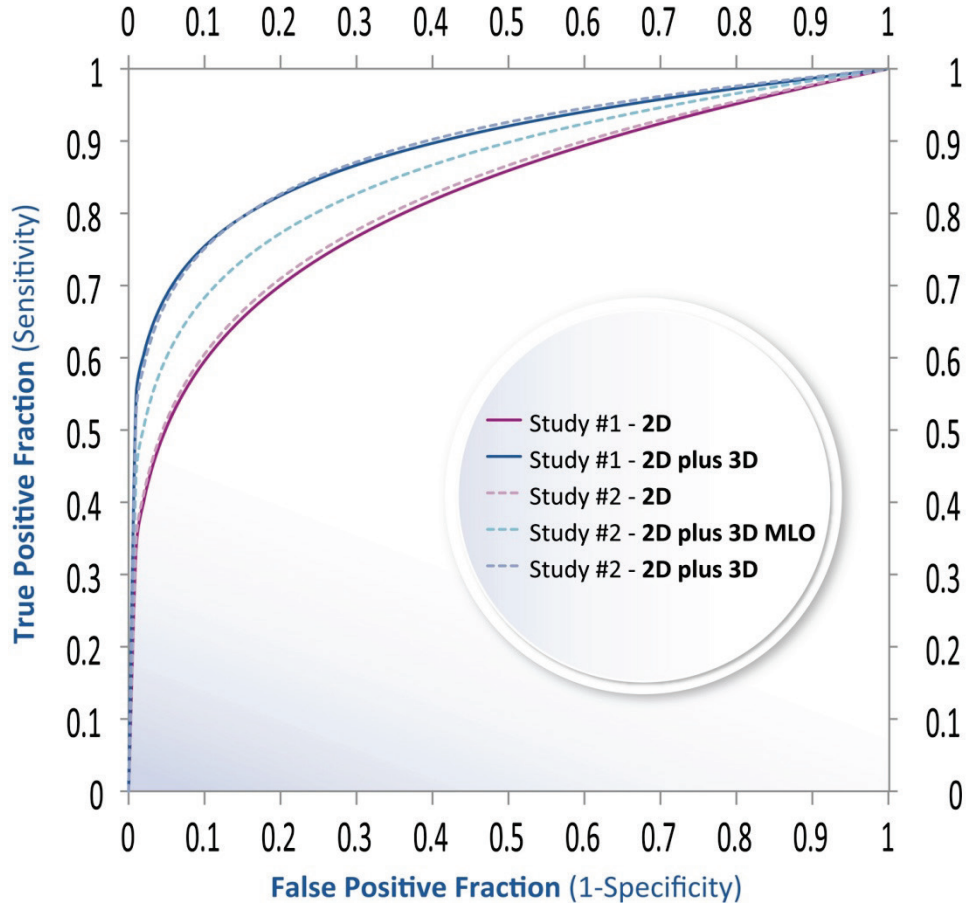
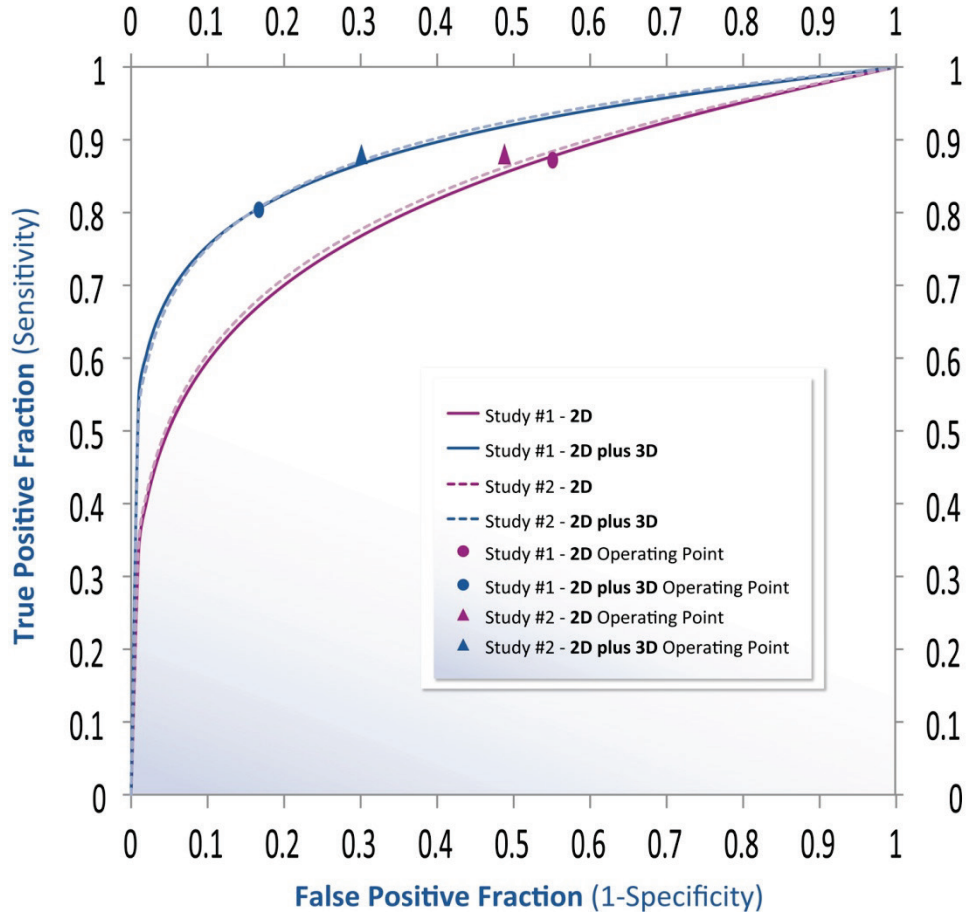


Figure 3: ROC and Operating Points for Reader Study 1 and Reader Study 2



It was observed that tomosynthesis was substantially more effective at improving the detection of masses versus for calcifications and that this, in addition to for the need to compare to priors, was an important reason for continuing to use 2D images in addition to 3D images for screening. Figure 4 and Figure 5 illustrate this point by showing the ROC improvements for masses and calcifications derived from the same data as Figure 1. Generally, superimposition of soft tissue structures does not degrade calcification visibility whereas it does degrade the visibility of masses and other soft tissue lesions. Since tomosynthesis removes tissue superimposition, it explains why the benefit for mass visibility is much greater than that for calcification visibility.

Figure 4: Pooled ROC curves for Calcification Cases; Reader Study 1 and Reader Study 2

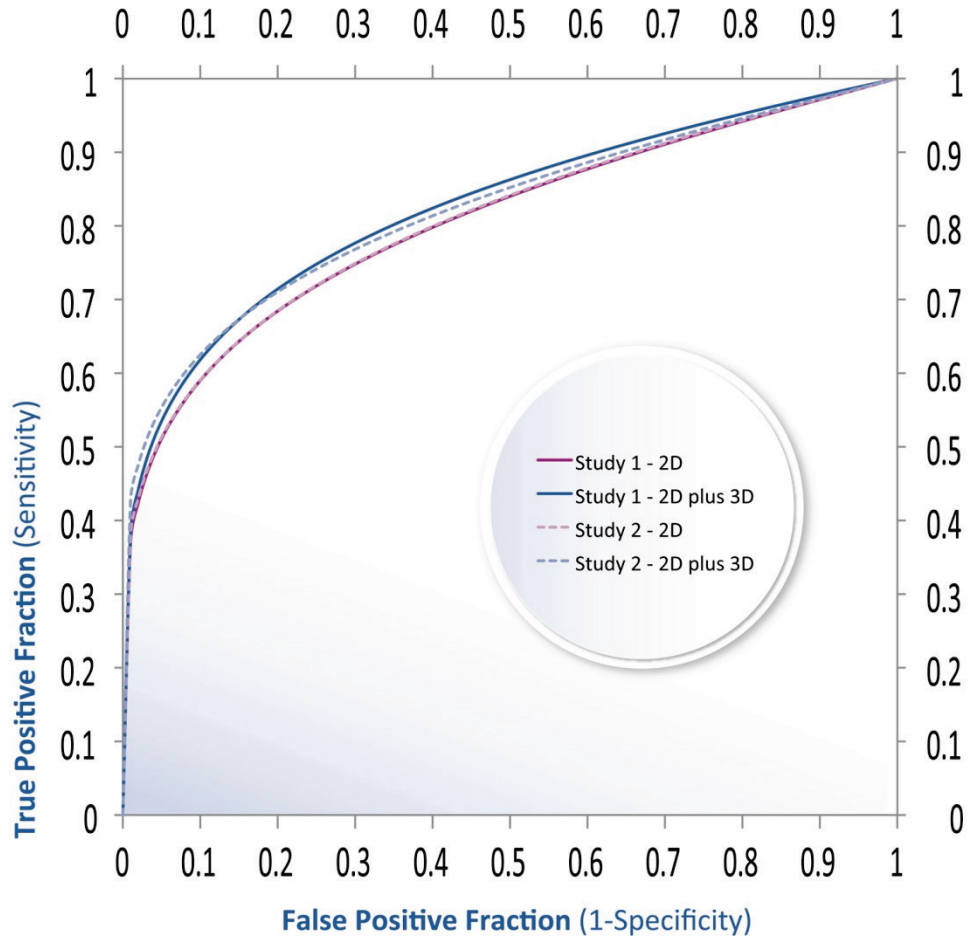
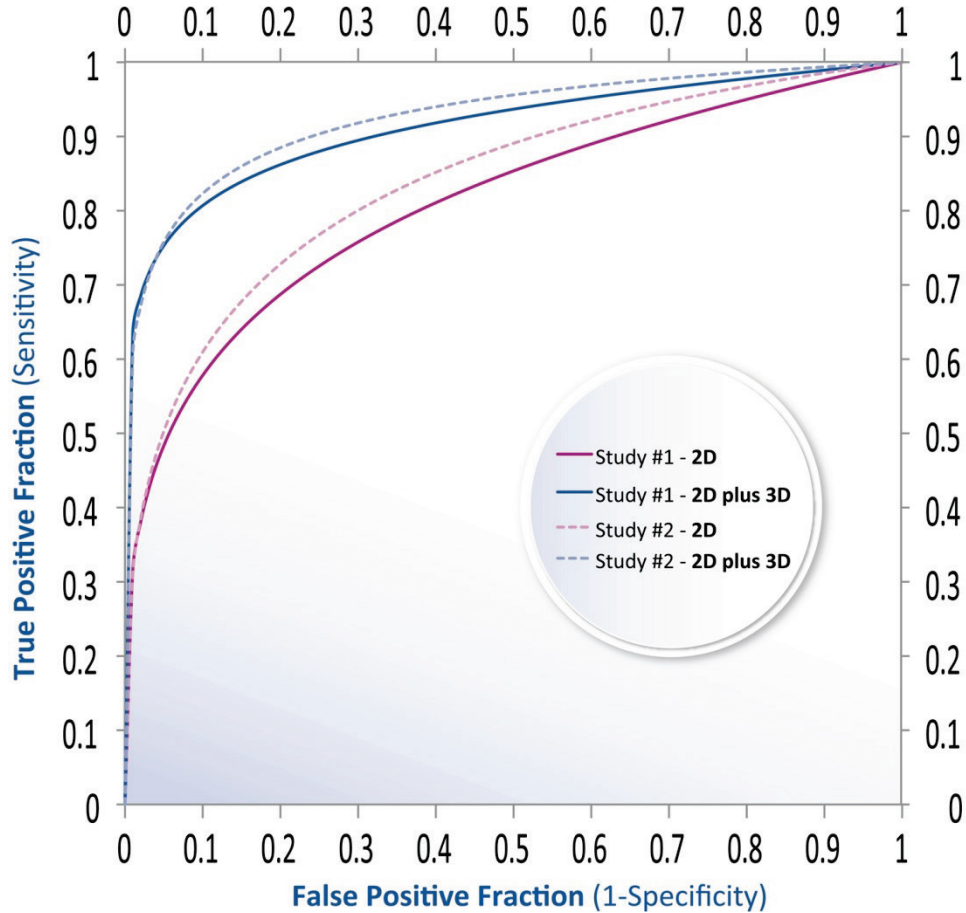


Figure 5: Pooled ROC curves for Non-Calcification Cases; Reader Study 1 and Reader Study 2



The clinical study results summarized above demonstrate that there is a significant benefit in using 2D plus 3D imaging for routine screening mammography. By using both imaging modalities the detection and characterization of calcifications remains at the same level as in the conventional mammogram and the detection and characterization of masses is significantly enhanced. In addition, the comparison with prior 2D images remains unchanged and there is a seamless learning curve available to the radiologist as tomosynthesis becomes integrated into clinical mammography screening.



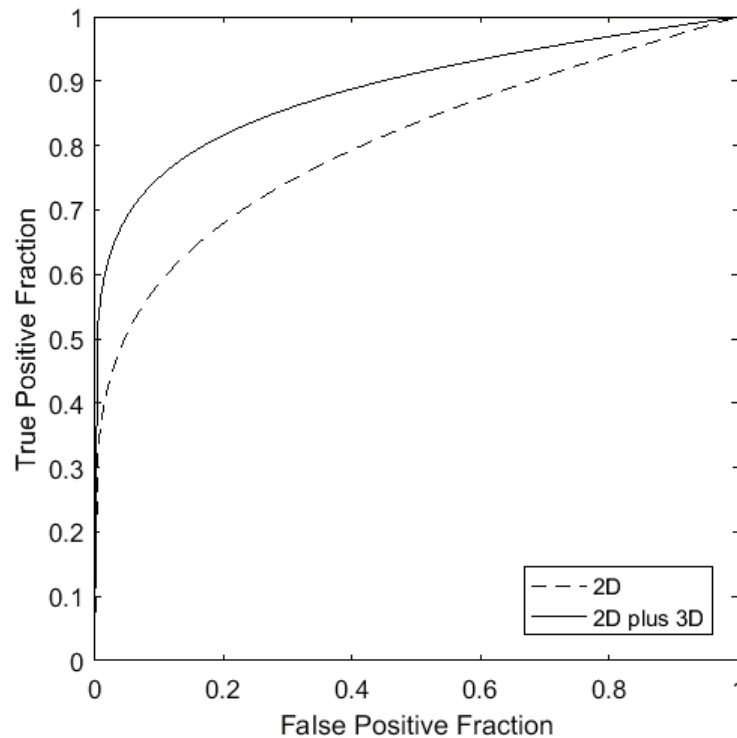
Note

For the Clinical Study Summary specific to synthesized 2D, see Selenia® Dimensions® and 3Dimensions™ Synthesized 2D Software Physician Labeling, MAN-03608.

1.8 Clinical Studies Summary- Dense Breast Data

Hologic compared the performance of 2D plus 3D breast imaging to conventional (2D) imaging in women with dense breasts. In this analysis, there were 25 cancer cases with dense breasts. There was a significant ($P < 0.001$) benefit to AUC (8.42%) in all dense breasts.

Figure 6: Pooled ROC Curves for Dense Breast Analysis; Reader Study 2



The clinical study results summarized above demonstrate that there is a significant benefit in using 2D plus 3D imaging for routine screening mammography in women with dense breasts. Screening accuracy was shown to increase when using 2D plus 3D compared to 2D imaging. In particular, 2D plus 3D demonstrated superior performance, as measured using area under the ROC curve, compared to 2D imaging in women with dense breasts. In summary, 2D plus 3D demonstrated superior performance compared to 2D imaging, both in all breast densities, and also in the subgroup of dense breasts.

1.9 Clinical Studies Summary - High Resolution Tomosynthesis

A preference study was conducted to compare the image quality for the Clarity HD high resolution tomosynthesis image sets to Standard Resolution tomosynthesis image sets. Seven MQSA-qualified radiologists reviewed 119 images that were acquired with both Clarity HD high-resolution and Standard Resolution. The radiologists had experience reading tomosynthesis images. Readers included in the evaluation study had a range of backgrounds and prior experience, as described in the following table:

Reader number	Practice type	Average Annual Mammography Interpretation Volume (Personal)	Breast Imaging Fellowship	Years Active	Years of Tomosynthesis Experience	Prior C-View Experience
1	Academic	3500+	Yes	2009- present	4	Yes
2	Community	6000+	No	1998-present	5	yes
3	Community	2000	No	1983-present	8	Yes
4	Academic	5000+	Yes	2004-present	7	Yes
5	Community	6000+	No	1993-present	7	Yes
6	Community	5000+	Yes	1994-Present	7	Yes
7	Community	2000	No	1982-present	7	Yes

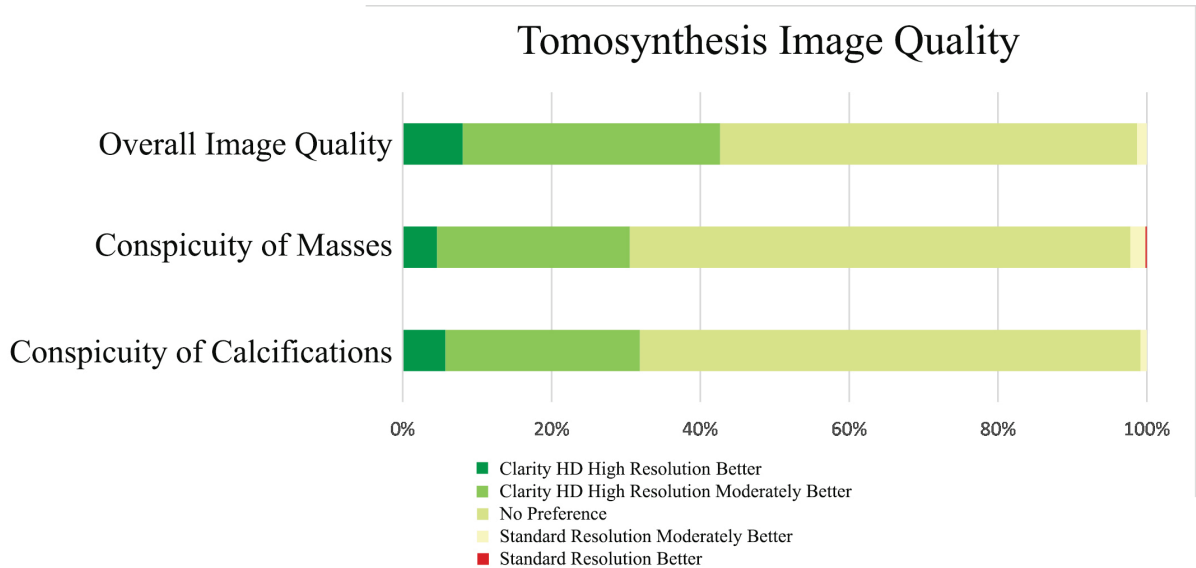
The cases represented a range of breast densities and mammographic findings. The distribution of case findings is shown in the following table:

	Malignant	Benign	Total
Mass Lesion	35	27	62
Calc Lesion	18	24	42
Mass and Calcification Lesion	7	3	10
Negative			5
Grand Total			119

In the reading session, the radiologists were asked to compare Overall Image Quality (including assessment of noise and artifacts), Conspicuity of Masses, and Conspicuity of Calcifications of two images, one of which was the Clarity HD high-resolution tomosynthesis image set and the other the Standard Resolution tomosynthesis image set. The images were blinded and occurred in random order on the left and right workstation monitors. The radiologist scored their preference as to which image set was superior, moderately better, or if there was no preference.

The results obtained from 833 readings (seven readers, 119 images) are shown in Figure 7. Overall Image Quality of the Clarity HD high-resolution images, Conspicuity of Masses, and Conspicuity of Calcifications were found to be equivalent to Standard Resolution Tomosynthesis images. In summary, 99% of readings for Overall Image Quality, 98% of readings involving masses, and 99% of readings involving calcifications were rated equivalent or better for Clarity HD high-resolution images as compared to Standard Resolution tomosynthesis images.

Figure 7: Tomosynthesis Image Quality Preferences
7 readers, 119 images. Overall Image Quality had no missing values. Conspicuity of Masses had 3 missing values of 504 responses (7 readers, 72 cases with masses). Conspicuity of Calcifications had 17 missing values of 364 responses (7 readers, 52 cases with calcifications).



1.10 Dose Comparison

	Standard Resolution	High Resolution
Mode	Dose (mGy) ¹	Dose (mGy) ¹
2D	1.20	1.20
3D	1.45	1.45
2D and 3D	2.65	2.65
Screen-Film ²	1.90	1.90

¹ 4.2cm compressed breast with composition of 50% glandularity

² Bloomquist AK, Yaffe MJ, Pisano ED et. al. Quality control for digital mammography in the ACRIN DMIST trial: part I. Med Phys 2006; 33: 719-736.