

# User Experience with Hologic Clarity HD™ and Intelligent 2D™ Technology

Georgia Giakoumis Spear, M.D.  
Chief of the Department of Breast Imaging, NorthShore University Health System

## Introduction

Our daily work and mission as breast-imaging radiologists is to detect breast cancer early and make a positive impact on women’s health. Over the years, NorthShore University Health System has adopted proven technological advances to increase our ability to detect breast cancers at the earliest stage, when they are manageable and treatable. We are a high volume practice, with a staff of 14 dedicated breast imagers performing approximately 90,000 mammograms per year.

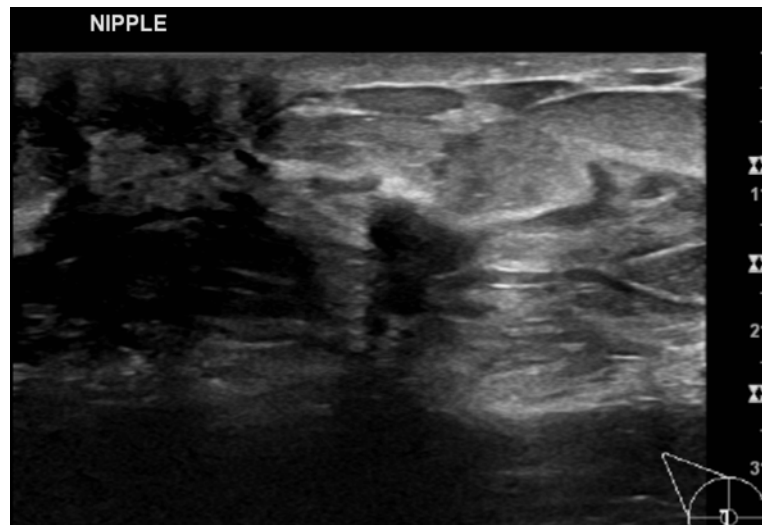We made the determination to transition all our mammography units to Hologic Clarity HD™ and Intelligent 2D™ technology when it received FDA approval in 2018. The improvements in image resolution, clarity, lesion characterization and a reduction in artifacts, along with a more natural appearance (similar to FFDM), were all important factors in our decision.

We began implementing the technology in October of 2018 and have completed the transition of 19 of our mammography units to Hologic 3Dimensions™ systems with Hologic Clarity HD™ and Intelligent 2D technology. We expect to transition our four remaining Selenia® Dimensions® systems by the end of the year. All future mammography units will be 3Dimensions with Hologic Clarity HD™ and Intelligent 2D.

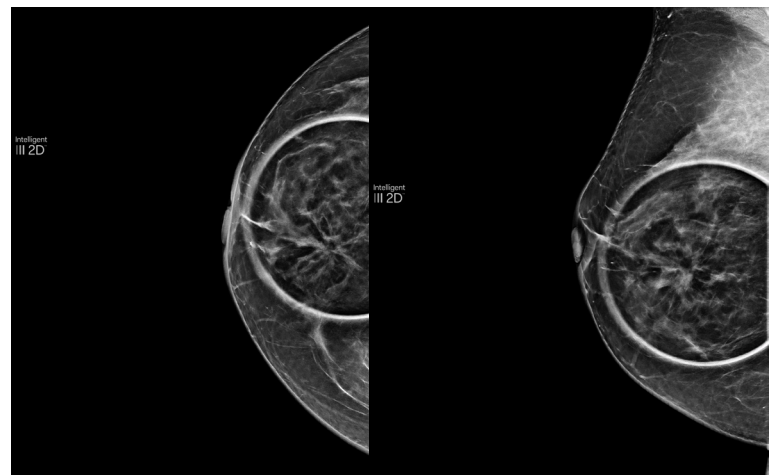
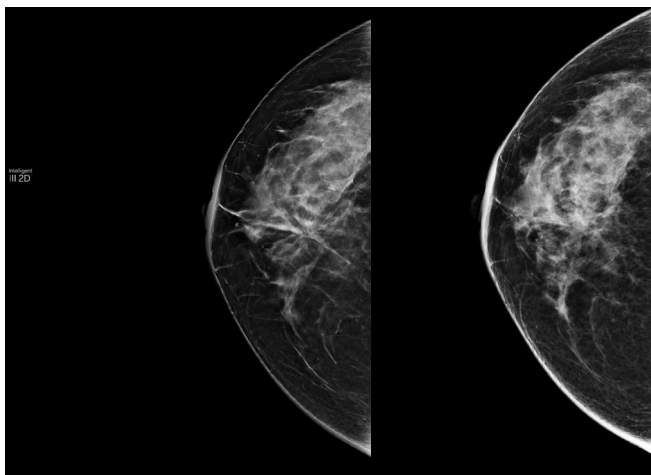
This paper discusses our transition from FFDM to synthesized 2D imaging and ultimately to Hologic Clarity HD™, the impact of the higher resolution imaging on NorthShore University Healthcare and our experiences implementing the new technology.


## Transitioning to Synthesized 2D Images

Hologic C-View™ technology was the first FDA-approved synthesized image to replace FFDM images in a combined tomosynthesis and FFDM screening study. C-View software automatically generates a synthesized 2D image directly from the tomosynthesis datasets in a 3.7 scan, lowering the radiation dose and decreasing the amount of time patients are in compression.



**Case 1.** 44 year old woman with stage 1A 8 mm IDC ER/PR positive





**Figure 1.** This shows synthesized images acquired using a contrast-detail phantom. The image on the left shows the C-View image and on the right is the same region on the Intelligent 2D image.

## Imaging

As we planned the transition from FFDM to C-View, we knew there would be a learning curve to adjust our eye to identify subtle changes in the breast tissue visible with C-View. Our radiology staff expressed some concern about the extra reading time required to train their eyes and that they would miss things they could have seen on the FFDM images. As the section chief, the concern was that if we did the FFDM + 3D combo, we would continue to rely on the FFDM because we were more comfortable with the images. As a result, we determined that based on our experience reading FFDM mammographic imaging in a high volume practice, the best methodology for us was to adapt quickly to the new C-View imaging sets, without reliance on FFDM mammographic imaging. This enabled us to reduce our learning curve and increase our efficiency.

## Hologic Clarity HD™ High-Resolution 3D™ Imaging

The new Hologic Clarity HD™ imaging acquires tomosynthesis imaging data at 70-microns – the gold standard in mammography. Intelligent 2D, which is the synthesized component, is created from the 70-micron tomosynthesis image set and results in a synthesized 2D image with a resolution of 70 microns. We immediately appreciated the 70-micron pixel size as the contrast resolution is significantly improved, giving a more ‘natural’ appearance to the images, similar to FFDM images.

With the Intelligent 2D images, the margins of lesions are more discrete, providing clearer delineation of mass margins, specifically for round and lobulated masses, increasing our confidence in identifying true positive malignancies. The skin line is distinct and the noise of the images is reduced, allowing for improved visualization of calcifications. Furthermore, Intelligent 2D images eliminate previously noted artifacts from calcifications and biopsy markers allowing for increased visibility of the breast parenchyma.

We have noticed an improvement in the sharpness of the images and improved contrast surrounding a lesion, with decreased density around noted lesions. This allows for better visualization of abnormalities and improved detection. Additionally, we can visualize calcifications better.

Our staff also reported that the higher resolution images made subtle architectural distortions more apparent and discrete, and they noted correlations with sonographic lesions. We began to diagnose small, invasive cancers that were previously hidden on 3D + C-View imaging.

## Transitioning from C-View to Intelligent 2D

From an interpretation standpoint, our transition to Intelligent 2D was simpler and easier than the transition from FFDM to C-View. Immediately after implementing Intelligent 2D our radiologists reported how much better the images were compared to C-View and they felt comfortable and confident they were actually detecting more than previously. They were positive about the resolution, image quality, and the

fact that the images looked so much more natural, and more similar to the FFDM images that we were used to seeing and comfortable reading.

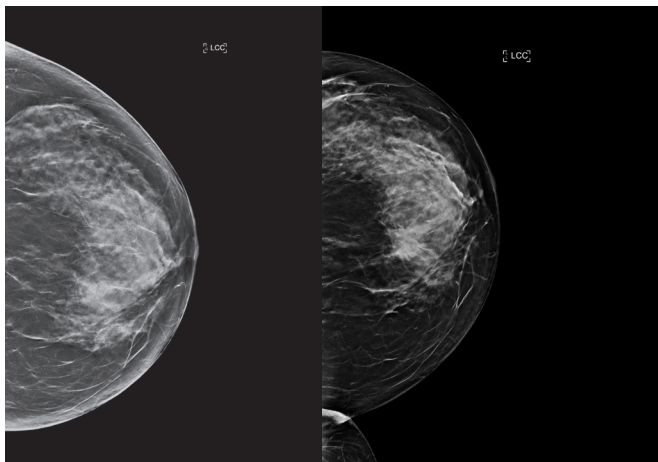
The improvements in resolution and visualization of the tissue with Hologic Clarity HD™ and Intelligent 2D are enabling us to reduce our interpretation time. We still look through all the tomosynthesis slices, but we are able to see everything much clearer, so there's less questioning. As our confidence in the images increases, we are able to make decisions more quickly and effectively.

### Reduction in Recall Rate

We are continuously evaluating the impact of tomosynthesis with Hologic Clarity HD™ on our cancer detection rates and recall rates. Our radiologists have unanimously expressed that greater confidence when we're reading cases with Hologic Clarity HD™ and Intelligent 2D technology has decreased our recall rates. We have examples where we've seen distortions on the Intelligent 2D images which we did not see on the prior year 3D + C-View images. We feel much more confident in the resolution and the image quality that we are seeing with Hologic Clarity HD™.

As an example, there was a patient imaged with Hologic Clarity HD™ in her screening mammogram where we noted several architectural distortions which we biopsied and found to be malignant. On the previous 3D + C-View imaging, we didn't appreciate that distortion as well. With Hologic Clarity HD™, we immediately saw an improvement in resolution and in the image quality.

**Case 2.** The advantage of Tomosynthesis demonstrates a 2.3 cm cancer and the non-visualization on 2D with the advantage of lesion detection on Clarity HD. It also shows lesion delineation in a dense breast.

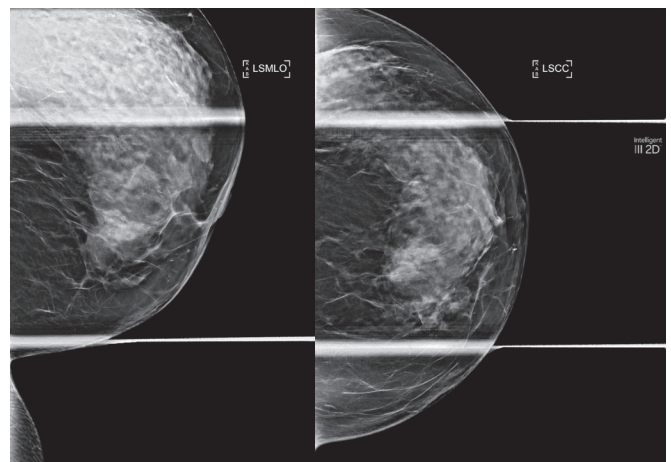
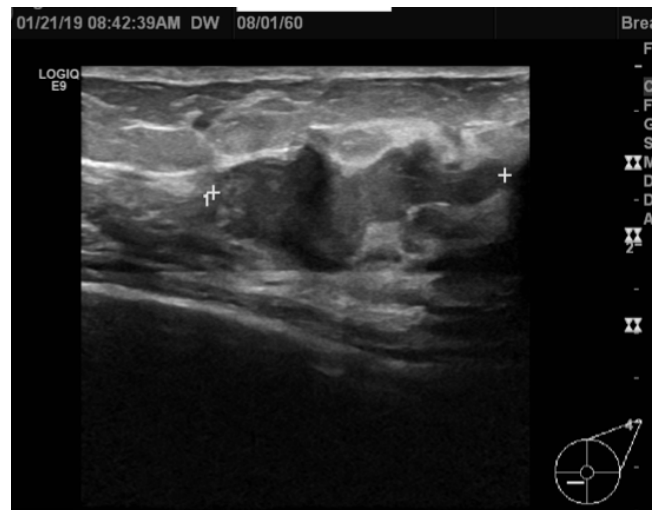

### Visualizing Calcifications with Hologic Clarity HD™

Within the first week of using Hologic Clarity HD™, we had a case where we saw calcifications on the Hologic Clarity HD™ imaging that were not visible on the prior FFDM images. We did spot compression

magnification views using FFDM, and we couldn't see the calcifications at all. We then brought the patient into the Hologic Clarity HD™ tomosynthesis room, noted we could see the calcifications, and conducted a tomo-guided biopsy. We found calcifications more accurately and rapidly on the Hologic Clarity HD™ imaging system than we did with FFDM, (and FFDM's claim to fame is calcifications). So, Hologic Clarity HD™ enables us to see calcifications vividly.

In another example, in a patient with dense breast tissue, the density was impeding our ability to see the calcifications on the FFDM images. Hologic Clarity HD™ imaging overcame some of the superimposition and highlighted the calcifications, and we



used Hologic Clarity HD™ 3D imaging to eventually to guide us through the biopsy. It's a perfect example of the kind of difference tomosynthesis and Hologic Clarity HD™ make.

## Building an IT Infrastructure

In preparation for the implementation of Hologic Clarity HD™, we worked closely with IT to ensure our infrastructure could handle the additional storage and bandwidth for the high-resolution 70-micron images. If you do not have an IT infrastructure capable of supporting the increase in file size, it may slow your workflow. Due to the large number of modalities in breast imaging and the integration needs in the workplace, I recommend closely working with IT to ensure that the infrastructure can support a seamless integration and optimal workflow.

## Implementation

We have a high-volume practice with nine imaging centers, so, we staggered the implementation of tomosynthesis over the course of a year in order to align purchases with our budgeting cycles. We began by transitioning one system in each site to ensure all patients throughout our NorthShore Healthcare system had access to tomosynthesis imaging. When each site had one system, we began replacing additional systems. Although we have not completed our transition to a 100% tomosynthesis mammography approach with Hologic Clarity HD™, we are headed in that direction.

Every tomosynthesis mammography room has Hologic Clarity HD™, but our current workflow is not based on tomosynthesis and Hologic Clarity HD™ alone. Unless a patient specifies a tomosynthesis mammogram, they are randomly assigned to

an imaging room and could have an FFDM scan. We have invested in educating our patients, our physicians, and our community about the benefits of tomosynthesis—as a result, on occasion, we have patients waiting for the tomosynthesis room.

## Conclusion

Our practice quickly began to see the benefits of Hologic Clarity HD™ in improved reading time, greater accuracy in the detection of distortions, and increasing confidence in both recalling patients and identifying true positive malignancies. Hologic Clarity HD™ is revolutionary in the arena of breast cancer screening and we know it is helping us make an impact on patient care and women's health.

We've been finding cancers with the new Hologic Clarity HD™ technology that we feel we wouldn't have seen before. We have entered a sweet spot in our confidence and ability to detect breast cancer early, when it is manageable and treatable. Tomosynthesis with Hologic Clarity HD™ and Intelligent 2D have afforded us confidence. You really can see a difference, and when you see that difference, it makes all the impact.

## References

Hooley, R, Durand M, Philpotts, L. Advances in Digital Breast Tomosynthesis. Regina J. Hooley, Melissa A. Durand, and Liane E. Philpotts. *American Journal of Roentgenology* 2017 208:2, 256-266

Vedantham S, Karellas A, Vijayaraghavan GR, Kopans DB. Digital breast tomosynthesis: state of the art. *Radiology* 2015; 277:663–684

Skaane P, Bandos AI, Eben E, et al. Two-view digital breast tomosynthesis screening with synthetically reconstructed projection images: comparison with digital breast tomosynthesis with full-field digital mammographic images. *Radiology* 2014; 271:655–663

### United States / Latin America

250 Campus Drive  
Marlborough, MA 01752 USA  
Tel: +1.877.371.4372  
Sales: +1.781.999.7453  
Fax: +1.781.280.0668  
www.hologic.com

WP-00143 Rev 002 (10/19) US/International © 2019 Hologic, Inc. All rights reserved.  
Printed in the USA. Specifications subject to change without notice. Hologic, Hologic Clarity HD, C-View, Dimensions, Intelligent 2D, SmartCurve and associated logos or trademarks are registered trademarks of Hologic, Inc. and/or subsidiaries in the United States and/or other countries. All other trademarks, registered trademarks, and product names are the property of their respective owners.