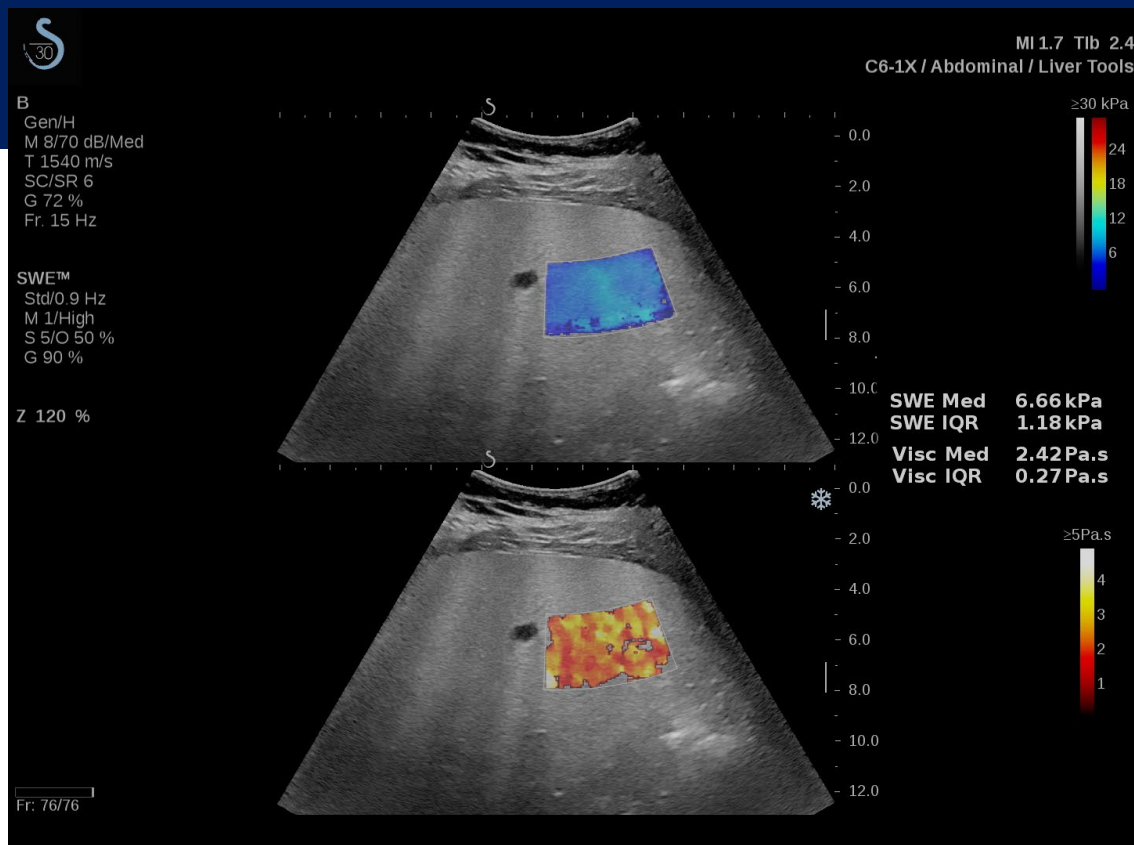


HOLOGIC[®]

PEER-REVIEWED ARTICLES

SHEARWAVE[™] ELASTOGRAPHY FOR LIVER AND ABDOMINAL IMAGING



1. Ozturk A, Mohammadi R, Pierce TT, et al. Diagnostic accuracy of shear wave elastography as a non-invasive biomarker of high-risk non-alcoholic steatohepatitis in patients with non-alcoholic fatty liver disease. *Ultrasound Med Biol.* 2020;46(4):972-980. doi: 10.1016/j.ultrasmedbio.2019.12.020.
2. Gatos I, Drazinos P, Yarmenitis S, et al. Comparison of sound touch elastography, shear wave elastography and vibration-controlled transient elastography in chronic liver disease assessment using liver biopsy as the "reference standard." *Ultrasound Med Biol.* 2020;46(4):959-971. doi: 10.1016/j.ultrasmedbio.2019.12.016.
3. Wang H, Zheng P, Sang L, et al. Does operator experience and the Q-box diameter affect the repeatability of liver stiffness measurements obtained by 2-dimensional shear wave elastography? *J Ultrasound Med.* 2020;39(4):741-747. doi: doi.org/10.1002/jum.15153.
4. Thiele M, Hugger MB, Kim Y, et al. 2D shear wave liver elastography by aixplorer to detect portal hypertension in cirrhosis: an individual patient data meta-analysis. *Liver Int.* 2020;40(6):1435-1446. doi: 10.1111/liv.14439.
5. Wei H, Jiang HY, Li M, et al. Two-dimensional shear wave elastography for significant liver fibrosis in patients with chronic hepatitis B: A systematic review and meta-analysis. *Eur J Radiol.* 2020;124:108839. doi: 10.1016/j.ejrad.2020.108839.
6. Song Y, Dang Y, Wang P, et al. CHD is associated with higher grades of NAFLD predicted by liver stiffness. *J Clin Gastroenterol.* 2020;54(3):271-277. doi: 10.1097/MCG.0000000000001238.
7. Jamialahmadi T, Jangjoo A, Rezvani R, et al. Hepatic function and fibrosis assessment via 2D-shear wave elastography and related biochemical markers pre- and post-gastric bypass surgery. *Obes Surg.* 2020;30(6):2251-2258. doi: 10.1007/s11695-020-04452-0.
8. Wu M, Wu L, Jin J, et al. Liver stiffness measured with two-dimensional shear-wave elastography is predictive of liver-related events in patients with chronic liver disease due to hepatitis B viral infection. *Radiology.* 2020;295(2):353-360. doi: 10.1148/radiol.2020191481.
9. Yang H, Sun Y, Tang Y, et al. Shear-wave elastography of the liver in a healthy pediatric population. *J Clin Ultrasound.* 2020;48(3):139-144. doi: 10.1002/jcu.22794.
10. Yan Y, Xing X, Lu Q, et al. Assessment of biopsy proven liver fibrosis by two-dimensional shear wave elastography in patients with primary biliary cholangitis. *Dig Liver Dis.* 2020;52(5):555-560. doi: 10.1016/j.dld.2020.02.002.
11. Dardanelli EP, Orozco ME, Lostra J, et al. Bidimensional shear-wave elastography for assessing liver fibrosis in children: A proposal of reference values that correlate with the histopathological Knodell-Ishak score. *Pediatr Radiol.* 2020;50(6):817-826. doi: 10.1007/s00247-020-04632-1.
12. Lee S, Kim MJ, Lee MJ, et al. Hepatic subcapsular or capsular flow in biliary atresia: is it useful imaging feature after the Kasai operation? *Eur Radiol.* 2020;30(6):3161-3167. doi: 10.1007/s00330-020-06656-5.
13. Fu J, Wu B, Wu H, et al. Accuracy of real-time shear wave elastography in staging hepatic fibrosis: A meta-analysis. *BMC Med Imaging.* 2020;20(1):16. doi: 10.1186/s12880-020-0414-5.
14. Shao C, Ye J, Li F, et al. Different predictors of steatosis and fibrosis severity among lean, overweight and obese patients with nonalcoholic fatty liver disease. *Dig Liver Dis.* 2019;51(10):1392-1399. doi: 10.1016/j.dld.2019.02.019.
15. Guo H, Liao M, Jin J, et al. How intrahepatic cholestasis affects liver stiffness in patients with chronic hepatitis B: A study of 1197 patients with liver biopsy. *Eur Radiol.* 2020;30(2):1096-1104. doi: 10.1007/s00330-019-06451-x.
16. Delahaye J, Bazeries P, Lannes A, et al. Doppler ultrasonography devices, including elastography, allow for accurate diagnosis of severe liver fibrosis. *Eur J Radiol.* 2018;108:133-139. doi: 10.1016/j.ejrad.2018.09.019.
17. Bayramov N, Yilmaz S, Salahova S, et al. Liver graft and spleen elastography after living liver transplantation: Our first results. *Transplant Proc.* 2019;51(7):2446-2450. doi: 10.1016/j.transproceed.2019.01.184.
18. Johari MI, Yusoff K, Haron J, et al. A randomised controlled trial on the effectiveness and adherence of modified alternate-day calorie restriction in improving activity of non-alcoholic fatty liver disease. *Sci Rep.* 2019;9(1):11232. doi: 10.1038/s41598-019-47763-8.
19. Jamialahmadi T, Nematy M, Jangjoo A, et al. Measurement of liver stiffness with 2D-shear wave elastography (2D-SWE) in bariatric surgery candidates reveals acceptable diagnostic yield compared to liver biopsy. *Obes Surg.* 2019;29(8):2585-2592. doi: 10.1007/s11695-019-03889-2.
20. Calvopina DA, Noble C, Weis A, et al. Supersonic shear-wave elastography and APRI for the detection and staging of liver disease in pediatric cystic fibrosis. *J Cyst Fibros.* 2019;S1569-1993(19)30820-3. doi: 10.1016/j.jcf.2019.06.017.

21. Park HS, Choe WH, Han HS, et al. Assessing significant fibrosis using imaging-based elastography in chronic hepatitis B patients: Pilot study. *World J Gastroenterol.* 2019;25(25):3256-3267. doi: 10.3748/wjg.v25.i25.3256.
22. Yu JB, Xiong H, Yuan XC, et al. Liver stiffness detected by shear wave elastography predicts esophageal varices in cirrhotic patients. *Ultrasound Q.* 2019; 10.1097/RUQ.0000000000000466. doi: 10.1097/RUQ.0000000000000466.
23. Kim DW, Suh CH, Kim KW, et al. Technical performance of two-dimensional shear wave elastography for measuring liver stiffness: A systematic review and meta-analysis. *Korean J Radiol.* 2019;20(6):880-893. doi: 10.3348/kjr.2018.0812.
24. Iijima H, Tada T, Kumada T, et al. Comparison of liver stiffness assessment by transient elastography and shear wave elastography using six ultrasound devices. *Hepatol Res.* 2019;49(6):676-686. doi: 10.1111/hepr.13319.
25. Zhu Y, Ding H, Fu T, et al. Portal hypertension in hepatitis B-related cirrhosis: Diagnostic accuracy of liver and spleen stiffness by 2-D shear-wave elastography. *Hepatol Res.* 2019;49(5):540-549. doi: 10.1111/hepr.13306.
26. Kim DW, Park C, Yoon HM, et al. Technical performance of shear wave elastography for measuring liver stiffness in pediatric and adolescent patients: A systematic review and meta-analysis. *Eur Radiol.* 2019;29(5):2560-2572. doi: 10.1007/s00330-018-5900-6.
27. Liu J, Li Y, Yang X, et al. Comparison of two-dimensional shear wave elastography with nine serum fibrosis indices to assess liver fibrosis in patients with chronic hepatitis B: A prospective cohort study. *Ultraschall Med.* 2019;40(2):237-246. doi: 10.1055/a-0796-6584.
28. Hu X, Huang X, Chen H, et al. Diagnostic effect of shear wave elastography imaging for differentiation of malignant liver lesions: A meta-analysis. *BMC Gastroenterol.* 2019;19(1):60. doi: 10.1186/s12876-019-0976-2.
29. Castera L, Friedrich-Rust M, Loomba R. Noninvasive assessment of liver disease in patients with nonalcoholic fatty liver disease. *Gastroenterology.* 2019;156(5):1264-1281.e4. doi: 10.1053/j.gastro.2018.12.036.
30. Wang Y, Jia L, Wang X, et al. Diagnostic performance of 2-D shear wave elastography for differentiation of hepatoblastoma and hepatic hemangioma in children under 3 years of age. *Ultrasound Med Biol.* 2019;45(6):1397-1406. doi: 10.1016/j.ultrasmedbio.2019.02.007.
31. Gatos I, Tsantis S, Spiliopoulos S, et al. Temporal stability assessment in shear wave elasticity images validated by deep learning neural network for chronic liver disease fibrosis stage assessment. *Med Phys.* 2019;46(5):2298-2309. doi: 10.1002/mp.13521.
32. Byenfeldt M, Elvin A, Fransson P. Influence of probe pressure on ultrasound-based shear wave elastography of the liver using comb-push 2-D technology. *Ultrasound Med Biol.* 2019;45(2):411-428. doi: 10.1016/j.ultrasmedbio.2018.09.023.
33. Paternostro R, Reiberger T, Bucsecs T. Elastography-based screening for esophageal varices in patients with advanced chronic liver disease. *World J Gastroenterol.* 2019;25(3):308-329. doi: 10.3748/wjg.v25.i3.308.
34. Ferraioli G, Wong VW, Castera L, et al. Liver ultrasound elastography: An update to the World Federation for Ultrasound in Medicine and Biology guidelines and recommendations. *Ultrasound Med Biol.* 2018;44(12):2419-2440. doi: 10.1016/j.ultrasmedbio.2018.07.008.
35. Jeong JY, Cho YS, Sohn JH. Role of two-dimensional shear wave elastography in chronic liver diseases: A narrative review. *World J Gastroenterol.* 2018;24(34):3849-3860. doi: 10.3748/wjg.v24.i34.3849.
36. Zhang W, Zhu Y, Zhang C, et al. Diagnostic accuracy of 2-dimensional shear wave elastography for the staging of liver fibrosis: A meta-analysis. *J Ultrasound Med.* 2018;38(3):733-740. doi: 10.1002/jum.14760.
37. Dhyani M, Xiang F, Li Q, et al. Ultrasound shear wave elastography: Variations of liver fibrosis assessment as a function of depth, force and distance from central axis of the transducer with a comparison of different systems. *Ultrasound Med Biol.* 2018;44(11):2209-2222. doi: 10.1016/j.ultrasmedbio.2018.07.003.
38. Zheng W, Zhou ZG, Wong CH, et al. Evaluation of liver parenchyma stiffness in patients with liver tumours: optimal strategy for shear wave elastography. *Eur Radiol.* 2019;29(3):1479-1488. doi: 10.1007/s00330-018-5676-8.
39. Gao Y, Zheng J, Liang P, et al. Liver fibrosis with two-dimensional US shear-wave elastography in participants with chronic hepatitis B: A prospective multicenter study. *Radiology.* 2018;289(2):407-415. doi: 10.1148/radiol.2018172479.
40. Zeng J, Zheng J, Jin JY, et al. Shear wave elastography for liver fibrosis in chronic hepatitis B: Adapting the cut-offs to alanine aminotransferase levels improves accuracy. *Eur Radiol.* 2019;29(2):857-865. doi: 10.1007/s00330-018-5621-x.

41. Rattansingh A, Amooshahi H, Menezes RJ, et al. Utility of shear-wave elastography to differentiate low from advanced degrees of liver fibrosis in patients with hepatitis C virus infection of native and transplant livers. *J Clin Ultrasound*. 2018;46(5):311-318. doi: 10.1002/jcu.22583.
42. Wang HW, Shi HN, Cheng J, et al. Real-time shear wave elastography (SWE) assessment of short- and long-term treatment outcome in Budd-Chiari syndrome: A pilot study. *PLoS One*. 2018;13(5):e0197550. doi: 10.1371/journal.pone.0197550.
43. Wang K, Lu X, Zhou H, et al. Deep learning radiomics of shear wave elastography significantly improved diagnostic performance for assessing liver fibrosis in chronic hepatitis B: A prospective multicentre study. *Gut*. 2019;68(4):729-741. doi: 10.1136/gutjnl-2018-316204.
44. Li C, Dhyani M, Bhan AK, et al. Diagnostic performance of shear wave elastography in patients with autoimmune liver disease. *J Ultrasound Med*. 2019;38(1):103-111. doi: 10.1002/jum.14668.
45. Kim YY, Kim MJ, Shin HJ, et al. Interconversion of elasticity measurements between two-dimensional shear wave elastography and transient elastography. *Med Ultrason*. 2018;20(2):127-133. doi: 10.11152/mu-1307.
46. Suh CH, Kim KW, Park SH, et al. Shear wave elastography as a quantitative biomarker of clinically significant portal hypertension: A systematic review and meta-analysis. *AJR Am J Roentgenol*. 2018;210(5):W185-W195. doi: 10.2214/AJR.17.18367.
47. Hamada K, Saitoh S, Nishino N, et al. Shear wave elastography predicts hepatocellular carcinoma risk in hepatitis C patients after sustained virological response. *PLoS One*. 2018;13(4):e0195173. doi: 10.1371/journal.pone.0195173.
48. Jin JY, Zheng YB, Zheng J, et al. 2D shear wave elastography combined with MELD improved prognostic accuracy in patients with acute-on-chronic hepatitis B liver failure. *Eur Radiol*. 2018;28(10):4465-4474. doi: 10.1007/s00330-018-5336-z.
49. Xie LT, Yan CH, Zhao QY, et al. Quantitative and noninvasive assessment of chronic liver diseases using two-dimensional shear wave elastography. *World J Gastroenterol*. 2018;24(9):957-970. doi: 10.3748/wjg.v24.i9.957.
50. Lee DH, Lee JM, Yoon JH, et al. Liver stiffness measured by two-dimensional shear-wave elastography: Prognostic value after radiofrequency ablation for hepatocellular carcinoma. *Liver Cancer*. 2018;7(1):65-75. doi: 10.1159/000484445.
51. Wang J, Wang Q, Yu G, et al. Correlation between liver stiffness measured by shear wave elastography and Child-Pugh classification. *J Ultrasound Med*. 2018;37(9):2191-2199. doi: 10.1002/jum.14569.
52. Praktijnjo M, Krabbe V, Pohlmann A, et al. Evolution of nodule stiffness might predict response to local ablative therapy: A series of patients with hepatocellular carcinoma. *PLoS One*. 2018;13(2):e0192897. doi: 10.1371/journal.pone.0192897.
53. Shin HJ, Kim MJ, Yoon CS, et al. Motion effects on the measurement of stiffness on ultrasound shear wave elastography: a moving liver fibrosis phantom study. *Med Ultrason*. 2018;1(1):14-20. doi: 10.11152/mu-1138.
54. Webb M, Zimran A, Dinur T, et al. Are transient and shear wave elastography useful tools in Gaucher disease? *Blood Cells Mol Dis*. 2018;68:143-147. doi: 10.1016/j.bcmd.2016.12.010.
55. Elkrief L, Ronot M, Andrade F, et al. Non-invasive evaluation of portal hypertension using shear-wave elastography: analysis of two algorithms combining liver and spleen stiffness in 191 patients with cirrhosis. *Aliment Pharmacol Ther*. 2018;47(5):621-630. doi: 10.1111/apt.14488.
56. Herrmann E, de Lédinghen V, Cassinotto C, et al. Assessment of biopsy-proven liver fibrosis by 2D-shear wave elastography: An individual patient data based meta-analysis. *Hepatology*. 2018;67(1):260-272. doi: 10.1002/hep.29179.
57. Zeng J, Huang Z, Jin J, et al. Diagnostic accuracy of 2-D shear wave elastography for the non-invasive staging of liver fibrosis in patients with elevated alanine aminotransferase levels. *Ultrasound Med Biol*. 2018;44(1):85-93. doi: 10.1016/j.ultrasmedbio.2017.09.011.
58. Piscaglia F, Salvatore V, Mulazzani L, et al. Differences in liver stiffness values obtained with new ultrasound elastography machines and Fibroscan: A comparative study. *Dig Liver Dis*. 2017;49(7):802-808. doi: 10.1016/j.dld.2017.03.001.
59. Dietrich CF, Bamber J, Berzigotti A, et al. EFSUMB guidelines and recommendations on the clinical use of liver ultrasound elastography, update 2017. *Ultraschall Med*. 2017;38(4):377-394. doi: 10.1055/s-0043-103955.
60. Takeuchi H, Sugimoto K, Oshiro H, et al. Liver fibrosis: Noninvasive assessment using supersonic shear imaging and FIB4 index in patients with non-alcoholic fatty liver disease. *J Med Ultrason*. 2018;45(2):243-249. doi: 10.1007/s10396-017-0840-3.
61. Yoon HM, Cho YA, Kim JR, et al. Real-time two-dimensional shear-wave elastography for liver stiffness in children: Interobserver variation and effect of breathing technique. *Eur J Radiol*. 2017;97:53-58. doi: 10.1016/j.ejrad.2017.10.011.

62. Jansen C, Möller P, Meyer C, et al. Increase in liver stiffness after transjugular intrahepatic portosystemic shunt is associated with inflammation and predicts mortality. *Hepatology*. 2018;67(4):1472-1484. doi: 10.1002/hep.29612.
63. Kim JR, Suh CH, Yoon HM, et al. The diagnostic performance of shear-wave elastography for liver fibrosis in children and adolescents: A systematic review and diagnostic meta-analysis. *Eur Radiol*. 2018;28(3):1175-1186. doi: 10.1007/s00330-017-5078-3.
64. Grgurevic I, Bokun T, Salkic NN, et al. Liver elastography malignancy prediction score for noninvasive characterization of focal liver lesions. *Liver Int*. 2018;38(6):1055-1063. doi: 10.1111/liv.13611.
65. Liu JH, Zou Y, Chang W, et al. Assessment of liver fibrosis using real-time shear-wave elastography for patients with hepatitis B E antigen-negative chronic hepatitis B and alanine transaminase <2 times the upper limit of normal. *Rev Invest Clin*. 2017;69(5):254-261. doi: 10.24875/ric.17002215.
66. Gerber L, Fitting D, Srikantharajah K, et al. Evaluation of 2D- shear wave elastography for characterization of focal liver lesions. *J Gastrointest Liver Dis*. 2017;26(3):283-290. doi: 10.15403/jgld.2014.1121.263.dsh.
67. Hong EK, Choi YH, Cheon JE, et al. Accurate measurements of liver stiffness using shear wave elastography in children and young adults and the role of the stability index. *Ultrasonography*. 2017;37(3):226-232. doi: 10.14366/usg.17025.
68. Mulazzani L, Salvatore V, Ravaioli F, et al. Point shear wave ultrasound elastography with Esaote compared to real-time 2D shear wave elastography with supersonic imagine for the quantification of liver stiffness. *J Ultrasound*. 2017;20(3):213-225. doi: 10.1007/s40477-017-0260-7.
69. Huang Z, Zheng W, Zhang YJ, et al. Assessing hepatic fibrosis using 2-D shear wave elastography in patients with liver tumors: A prospective single-center study. *Ultrasound Med Biol*. 2017;43(11):2522-2529. doi: 10.1016/j.ultrasmedbio.2017.07.003.
70. Sariyeva E, Salahova S, Bayramov N. Importance of shear wave elastography of livers in practically healthy pregnant women. *Georgian Med News*. 2017;(268-269):43-47.
71. Wong RJ, Le A, Nguyen MT, et al. Significant hepatic fibrosis among treatment-naive chronic hepatitis B virus with increased hepatitis B virus DNA and normal alanine aminotransferase. *Clin Gastroenterol Hepatol*. 2018;16(1):146-148. doi: 10.1016/j.cgh.2017.07.012.
72. Paul SB, Das P, Mahanta M, et al. Assessment of liver fibrosis in chronic hepatitis: comparison of shear wave elastography and transient elastography. *Abdom Radiol*. 2017;42(12):2864-2873. doi: 10.1007/s00261-017-1213-5.
73. Zeng J, Zheng J, Huang Z, et al. Comparison of 2-D shear wave elastography and transient elastography for assessing liver fibrosis in chronic hepatitis B. *Ultrasound Med Biol*. 2017;43(8):1563-1570. doi: 10.1016/j.ultrasmedbio.2017.03.014.
74. Zhuang Y, Ding H, Zhang Y, et al. Two-dimensional shear-wave elastography performance in the noninvasive evaluation of liver fibrosis in patients with chronic hepatitis B: Comparison with serum fibrosis indexes. *Radiology*. 2017;283(3):873-882. doi: 10.1148/radiol.2016160131.
75. Gatos I, Tsantis S, Spiliopoulos S, et al. A machine-learning algorithm toward color analysis for chronic liver disease classification, employing ultrasound shear wave elastography. *Ultrasound Med Biol*. 2017;43(9):1797-1810. doi: 10.1016/j.ultrasmedbio.2017.05.002.
76. Yoon HM, Kim SY, Kim KM, et al. Liver stiffness measured by shear-wave elastography for evaluating intrahepatic portal hypertension in children. *J Pediatr Gastroenterol Nutr*. 2017;64(6):892-897. doi: 10.1097/MPG.0000000000001517.
77. Dhyani M, Grajo JR, Bhan AK, et al. Validation of shear wave elastography cutoff values on the supersonic aiplorer for practical clinical use in liver fibrosis staging. *Ultrasound Med Biol*. 2017;43(6):1125-1133. doi: 10.1016/j.ultrasmedbio.2017.01.022.
78. Shen Y, Zhou C, Zhu G, et al. Liver stiffness assessed by shear wave elastography predicts postoperative liver failure in patients with hepatocellular carcinoma. *J Gastrointest Surg*. 2017;21(9):1471-1479. doi: 10.1007/s11605-017-3443-9.
79. Yoon K, Jeong WK, Kim Y, et al. 2-Dimensional shear wave elastography: Interobserver agreement and factors related to interobserver discrepancy. *PLoS One*. 2017;12(4):e0175747. doi: 10.1371/journal.pone.0175747.
80. Stefanescu H, Allegretti G, Salvatore V, et al. Bidimensional shear wave ultrasound elastography with supersonic imaging to predict presence of oesophageal varices in cirrhosis. *Liver Int*. 2017;37(9):1405. doi: 10.1111/liv.13418.
81. Tada T, Kumada T, Toyoda H, et al. Improvement of liver stiffness in patients with hepatitis C virus infection who received direct-acting antiviral therapy and achieved sustained virological response. *J Gastroenterol Hepatol*. 2017;32(12):1982-1988. doi: 10.1111/jgh.13788.

82. Madhusudhan KS, Sharma R, Kilambi R, et al. 2D shear wave elastography of liver in patients with primary extrahepatic portal vein obstruction. *J Clin Exp Hepatol.* 2017;7(1):23-27. doi: 10.1016/j.jceh.2016.12.001.
83. Zhou LY, Jiang H, Shan QY, et al. Liver stiffness measurements with supersonic shear wave elastography in the diagnosis of biliary atresia: A comparative study with grey-scale US. *Eur Radiol.* 2017;27(8):3474-3484. doi: 10.1007/s00330-016-4710-y.
84. Shin HJ, Kim MJ, Kim HY, et al. Optimal acquisition number for hepatic shear wave velocity measurements in children. *PLoS One.* 2016;11(12):e0168758. doi: 10.1371/journal.pone.0168758.
85. Garcovich M, Veraldi S, Di Stasio E, et al. Liver stiffness in pediatric patients with fatty liver disease: Diagnostic accuracy and reproducibility of shear-wave elastography. *Radiology.* 2017;283(3):820-827. doi: 10.1148/radiol.2016161002.
86. Lupşor-Platon M, Badea R, Gersak M, et al. Noninvasive assessment of liver diseases using 2D shear wave elastography. *J Gastrointest Liver Dis.* 2016;25(4):525-532. doi: 10.15403/jgld.2014.1121.254.lup.
87. Sun LL, Dong G, Wang B, et al. Real-time shear wave elastography and APRI index for evaluating autoimmune hepatitis fibrosis. *J Biol Regul Homeost Agents.* 2016;30(4):1019-1021.
88. Poynard T, Pham T, Perazzo H, et al. Real-time shear wave versus transient elastography for predicting fibrosis: Applicability, and impact of inflammation and steatosis. A non-invasive comparison. *PLoS One.* 2016;11(10):e0163276. doi: 10.1371/journal.pone.0163276.
89. Sun LL, Chang W, Jiao LQ, et al. Hepatic fibrosis and supersonic shear imaging in patients with different etiological chronic hepatic diseases. *J Biol Regul Homeost Agents.* 2016;30(3):761-765.
90. Jansen C, Bogs C, Verlinden W, et al. Shear-wave elastography of the liver and spleen identifies clinically significant portal hypertension: A prospective multi-center study. *Liver Int.* 2017;37(3):396-405. doi: 10.1111/liv.13243.
91. Tian WS, Lin MX, Zhou LY, et al. Maximum value measured by 2D shear wave elastography helps in differentiating malignancy from benign focal liver lesions. *Ultrasound Med Biol.* 2016;42(9):2156-2166. doi: 10.1016/j.ultrasmedbio.2016.05.002.
92. Pellot-Barakat C, Chami L, Correas JM, et al. Does motion affect liver stiffness estimates in shear wave elastography? Phantom and clinical study. *Eur J Radiol.* 2016;85(9):1645-1650. doi: 10.1016/j.ejrad.2016.07.001.
93. Pawluś A, Inglot M, Chabowski M, et al. Shear wave elastography (SWE) of the spleen in patients with hepatitis B and C but without significant liver fibrosis. *Br J Radiol.* 2016;89(1066):20160423. doi: 10.1259/bjr.20160423.
94. Chen S, Liao B, Zhong Z, et al. Supersonic shearwave elastography in the assessment of liver fibrosis for postoperative patients with biliary atresia. *Sci Rep.* 2016;6:31057. doi: 10.1038/srep31057.
95. Wang X, Qian L, Jia L, et al. Utility of shear wave elastography for differentiating biliary atresia from infantile hepatitis syndrome. *J Ultrasound Med.* 2016;35(7):1475-1479. doi: 10.7863/ultra.15.08031.
96. Kim TY, Kim TY, Kim Y, et al. Diagnostic performance of shear wave elastography for predicting esophageal varices in patients with compensated liver cirrhosis. *J Ultrasound Med.* 2016;35(7):1373-1381. doi: 10.7863/ultra.15.07024.
97. Thiele M, Madsen BS, Procopet B, et al. Reliability criteria for liver stiffness measurements with real-time 2D shear wave elastography in different clinical scenarios of chronic liver disease. *Ultraschall Med.* 2016;38(6):648-654. doi: 10.1055/s-0042-108431. 10.1055/s-0042-108431.
98. Jansen C, Bogs C, Verlinden W, et al. Algorithm to rule out clinically significant portal hypertension combining Shear-wave elastography of liver and spleen: a prospective multicentre study. *Gut.* 2016;65(6):1057-1058. doi: 10.1136/gutjnl-2016-311536.
99. Belei O, Sporea I, Gradinaru-Tascau O, et al. Comparison of three ultrasound based elastographic techniques in children and adolescents with chronic diffuse liver diseases. *Med Ultrason.* 2016;18(2):145-150. doi: 10.11152/mu.2013.2066.182.bet.
100. Verlinden W, Bourgeois S, Gigase P, et al. Liver fibrosis evaluation using real-time shear wave elastography in hepatitis C-monoinfected and human immunodeficiency virus/hepatitis C-coinfected patients. *J Ultrasound Med.* 2016;35(6):1299-1308. doi: 10.7863/ultra.15.08066.
101. Varbobitis IC, Siakavellas SI, Koutsounas IS, et al. Reliability and applicability of two-dimensional shear-wave elastography for the evaluation of liver stiffness. *Eur J Gastroenterol Hepatol.* 2016;28(10):1204-1209. doi: 10.1097/MEG.0000000000000686.
102. Wu T, Wang P, Zhang T, et al. Comparison of two-dimensional shear wave elastography and real-time tissue elastography for assessing liver fibrosis in chronic hepatitis B. *Dig Dis.* 2016;34(6):640-649. doi: 10.1159/000448825.

103. Li C, Zhang C, Li J, et al. Diagnostic accuracy of real-time shear wave elastography for staging of liver fibrosis: A meta-analysis. *Med Sci Monit.* 2016;22:1349-1359. doi: 10.12659/MSM.895662.
104. Jansen C, Bogs C, Krag A, et al. Sequential shear-wave elastography of liver and spleen rules out clinically significant portal hypertension in compensated advanced chronic liver disease. *Gut.* 2016;66(3):558-559. doi: 10.1136/gutjnl-2016-311955.
105. Kutty SS, Zhang M, Danford DA, et al. Hepatic stiffness in the bidirectional cavopulmonary circulation: The liver adult-pediatric-congenital-heart-disease dysfunction study group. *J Thorac Cardiovasc Surg.* 2016;151(3):678-684. doi: 10.1016/j.jtcvs.2015.09.079.
106. Gatos I, Tsantis S, Spiliopoulos S, et al. A new computer aided diagnosis system for evaluation of chronic liver disease with ultrasound shear wave elastography imaging. *Med Phys.* 2016;43(3):1428-1436. doi: 10.1118/1.4942383.
107. Shan QY, Liu BX, Tian WS, et al. Elastography of shear wave speed imaging for the evaluation of liver fibrosis: A meta-analysis. *Hepatol Res.* 2016;46(12):1203-1213. doi: 10.1111/hepr.12669.
108. Feng JC, Li J, Wu XW, et al. Diagnostic accuracy of supersonic shear imaging for staging of liver fibrosis: A meta-analysis. *J Ultrasound Med.* 2016;35(2):329-339. doi: 10.7863/ultra.15.03032.
109. Franchi-Abella S, Corno L, Gonzales E, et al. Feasibility and diagnostic accuracy of supersonic shear-wave elastography for the assessment of liver stiffness and liver fibrosis in children: A pilot study of 96 patients. *Radiology.* 2016;278(2):554-562. doi: 10.1148/radiol.2015142815.
110. Piscaglia F, Salvatore V, Mulazzani L, et al. Ultrasound shear wave elastography for liver disease. A critical appraisal of the many actors on the stage. *Ultraschall Med.* 2016;37(1):1-5. doi: 10.1055/s-0035-1567037.
111. Guibal A, Renosi G, Rode A, et al. Shear wave elastography: An accurate technique to stage liver fibrosis in chronic liver diseases. *Diagn Interv Imaging.* 2016;97(1):91-99. doi: 10.1016/j.diii.2015.11.001.
112. Thiele M, Detlefsen S, Sevelsted Møller L, et al. Transient and 2-dimensional shear-wave elastography provide comparable assessment of alcoholic liver fibrosis and cirrhosis. *Gastroenterology.* 2016;150(1):123-133. doi: 10.1053/j.gastro.2015.09.040.
113. Jiang T, Tian G, Zhao Q, et al. Diagnostic accuracy of 2D-shear wave elastography for liver fibrosis severity: A meta-analysis. *PLoS One.* 2016;11(6):e0157219. doi: 10.1371/journal.pone.0157219.
114. Cassinotto C, Boursier J, De Ledinghen V, et al. Liver stiffness in nonalcoholic fatty liver disease: A comparison of supersonic shear imaging, FibroScan and ARFI with liver biopsy. *Hepatology.* 2016;63(6):1817-1827. doi: 10.1002/hep.28394.
115. Park HS, Kim YJ, Yu MH, et al. Shear wave elastography of focal liver lesion: Intraobserver reproducibility and elasticity characterization. *Ultrasound Q.* 2015;31(4):262-271. doi: 10.1097/RUQ.0000000000000175.
116. Dhyani M, Gee MS, Misdraji J, et al. Feasibility study for assessing liver fibrosis in paediatric and adolescent patients using real-time shear wave elastography. *J Med Imaging Radiat Oncol.* 2015;59(6):687-694. doi: 10.1111/1754-9485.12388.
117. Kim TY, Jeong WK, Sohn JH, et al. Evaluation of portal hypertension by real-time shear wave elastography in cirrhotic patients. *Liver Int.* 2015;35(11):2416-2424. doi: 10.1111/liv.12846.
118. Brunel T, Guibal A, Boularan C, et al. Focal nodular hyperplasia and hepatocellular adenoma: The value of shear wave elastography for differential diagnosis. *Eur J Radiol.* 2015;84(11):2059-2064. doi: 10.1016/j.ejrad.2015.07.029.
119. Alison M, Biran V, Tanase A, et al. Quantitative shear-wave elastography of the liver in preterm neonates with intra-uterine growth restriction. *PLoS One.* 2015;10(11):e0143220. doi: 10.1371/journal.pone.0143220.
120. Grgurevic I, Puljiz Z, Brnic D, et al. Liver and spleen stiffness and their ratio assessed by real-time two dimensional-shear wave elastography in patients with liver fibrosis and cirrhosis due to chronic viral hepatitis. *Eur Radiol.* 2015;25(11):3214-3221. doi: 10.1007/s00330-015-3728-x.
121. Grgurević I, Bokun T, Mustapić S, et al. Real-time two-dimensional shear wave ultrasound elastography of the liver is a reliable predictor of clinical outcomes and the presence of esophageal varices in patients with compensated liver cirrhosis. *Croat Med J.* 2015;56(5):470-481. doi: 10.3325/cmj.2015.56.470.
122. Tada T, Kumada T, Toyoda H, et al. Utility of real-time shear wave elastography for assessing liver fibrosis in patients with chronic hepatitis C infection without cirrhosis: Comparison of liver fibrosis indices. *Hepatol Res.* 2015;45(10):E122-129. doi: 10.1111/hepr.12476.
123. Gerber L, Kasper D, Fitting D, et al. Assessment of liver fibrosis with 2-D shear wave elastography in comparison to transient elastography and acoustic radiation force impulse imaging in patients with chronic liver disease. *Ultrasound Med Biol.* 2015;41(9):2350-2359. doi: 10.1016/j.ultrasmedbio.2015.04.014.

124. Bota S, Paternostro R, Etschmaier A, et al. Performance of 2-D shear wave elastography in liver fibrosis assessment compared with serologic tests and transient elastography in clinical routine. *Ultrasound Med Biol*. 2015;41(9):2340-2349. doi: 10.1016/j.ultrasmedbio.2015.04.013.
125. Webb M, Shibolet O, Halpern Z, et al. Assessment of liver and spleen stiffness in patients with myelofibrosis using FibroScan and shear wave elastography. *Ultrasound Q*. 2015;31(3):166-169. doi: 10.1097/RUQ.0000000000000139.
126. Yoneda M, Thomas E, Sclair SN, et al. Supersonic shear imaging and transient elastography with the XL probe accurately detect fibrosis in overweight or obese patients with chronic liver disease. *Clin Gastroenterol Hepatol*. 2015;13(8):1502-1509.e5. doi: 10.1016/j.cgh.2015.03.014.
127. Cassinotto C, Charrie A, Mouries A, et al. Liver and spleen elastography using supersonic shear imaging for the non-invasive diagnosis of cirrhosis severity and oesophageal varices. *Dig Liver Dis*. 2015;47(8):695-701. doi: 10.1016/j.dld.2015.04.008.
128. Bas A, Samanci C, Gulsen F, et al. Evaluation of liver stiffness after radioembolization by Real-Time ShearWave™ Elastography: Preliminary study. *Cardiovasc Intervent Radiol*. 2015;38(4):957-963. doi: 10.1007/s00270-014-1021-z.
129. Kim HJ, Lee HK, Cho JH, et al. Quantitative comparison of transient elastography (TE), shear wave elastography (SWE) and liver biopsy results of patients with chronic liver disease. *J Phys Ther Sci*. 2015;27(8):2465-2468. doi: 10.1589/jpts.27.2465.
130. Kasai Y, Moriyasu F, Saito K, et al. Value of shear wave elastography for predicting hepatocellular carcinoma and esophagogastric varices in patients with chronic liver disease. *J Med Ultrason*. 2015;42(3):349-355. doi: 10.1007/s10396-014-0603-3.
131. Imai Y, Taira J, Okada M, et al. The close linkage between the elasticity modulus measured by real-time mapping shear wave elastography and the presence of hepatocellular carcinoma in patients with a sustained virological response to interferon for chronic hepatitis C. *J Med Ultrason*. 2015;42(3):341-347. doi: 10.1007/s10396-014-0604-2.
132. Procopet B, Berzigotti A, Abraldes JG, et al. Real-time shear-wave elastography: applicability, reliability and accuracy for clinically significant portal hypertension. *J Hepatol*. 2015;62(5):1068-1075. doi: 10.1016/j.jhep.2014.12.007.
133. Elkrief L, Rautou PE, Ronot M, et al. Prospective comparison of spleen and liver stiffness by using shear-wave and transient elastography for detection of portal hypertension in cirrhosis. *Radiology*. 2015;275(2):589-598. doi: 10.1148/radiol.14141210.
134. Zheng J, Guo H, Zeng J, et al. Two-dimensional shear-wave elastography and conventional US: the optimal evaluation of liver fibrosis and cirrhosis. *Radiology*. 2015;275(1):290-300. doi: 10.1148/radiol.14140828.
135. Samir AE, Dhyani M, Vij A, et al. Shear-wave elastography for the estimation of liver fibrosis in chronic liver disease: determining accuracy and ideal site for measurement. *Radiology*. 2015;274(3):888-896. doi: 10.1148/radiol.14140839.
136. Zaleska-Dorobisz U, Pawluś A, Kucharska M, et al. SWE elastography in assessment of liver fibrosis. *Postepy Hig Med Dosw (Online)*. 2015;69:221-226. doi: 10.5604/17322693.1140338.
137. Ronot M, Di Renzo S, Gregoli B, et al. Characterization of fortuitously discovered focal liver lesions: additional information provided by shearwave elastography. *Eur Radiol*. 2015;25(2):346-358. doi: 10.1007/s00330-014-3370-z.
138. Deffieux T, Gennisson JL, Bousquet L, et al. Investigating liver stiffness and viscosity for fibrosis, steatosis and activity staging using shear wave elastography. *J Hepatol*. 2015;62(2):317-324. doi: 10.1016/j.jhep.2014.09.020.
139. Choi SY, Jeong WK, Kim Y, et al. Shear-wave elastography: A noninvasive tool for monitoring changing hepatic venous pressure gradients in patients with cirrhosis. *Radiology*. 2014;273(3):917-926. doi: 10.1148/radiol.14140008.
140. Huang Z, Zheng J, Zeng J, et al. Normal liver stiffness in healthy adults assessed by real-time shear wave elastography and factors that influence this method. *Ultrasound Med Biol*. 2014;40(11):2549-2555. doi: 10.1016/j.ultrasmedbio.2014.05.008.
141. Jeong JY, Kim TY, Sohn JH, et al. Real time shear wave elastography in chronic liver diseases: accuracy for predicting liver fibrosis, in comparison with serum markers. *World J Gastroenterol*. 2014;20(38):13920-13929. doi: 10.3748/wjg.v20.i38.13920.
142. Cassinotto C, Lapuyade B, Mouries A, et al. Non-invasive assessment of liver fibrosis with impulse elastography: Comparison of supersonic shear imaging with ARFI and FibroScan®. *J Hepatol*. 2014;61(3):550-557. doi: 10.1016/j.jhep.2014.04.044.
143. Beland MD, Brown SF, Machan JT, et al. A pilot study estimating liver fibrosis with ultrasound shear-wave elastography: Does the cause of liver disease or location of measurement affect performance? *AJR Am J Roentgenol*. 2014;203(3):W267-273. doi: 10.2214/AJR.13.11718.

144. Ozmen E, Adaletli I, Kayadibi Y, et al. The impact of shear wave elastography in differentiation of hepatic hemangioma from malignant liver tumors in pediatric population. *Eur J Radiol.* 2014;83(9):1691-1697. doi: 10.1016/j.ejrad.2014.06.002.
145. Zeng J, Liu GJ, Huang ZP, et al. Diagnostic accuracy of two-dimensional shear wave elastography for the non-invasive staging of hepatic fibrosis in chronic hepatitis B: a cohort study with internal validation. *Eur Radiol.* 2014;24(10):2572-2581. doi: 10.1007/s00330-014-3292-9.
146. Huang ZP, Zhang XL, Zeng J, et al. Study of detection times for liver stiffness evaluation by shear wave elastography. *World J Gastroenterol.* 2014;20(28):9578-9584. doi: 10.3748/wjg.v20.i28.9578.
147. Suh CH, Kim SY, Kim KW, et al. Determination of normal hepatic elasticity by using real-time shear-wave elastography. *Radiology.* 2014;271(3):895-900. doi: 10.1148/radiol.14131251.
148. Sporea I, Bota S, Grădinaru-Tașcău O, et al. Which are the cut-off values of 2D-shear wave elastography (2D-SWE) liver stiffness measurements predicting different stages of liver fibrosis, considering transient elastography (TE) as the reference method? *Eur J Radiol.* 2014;83(3):e118-122. doi: 10.1016/j.ejrad.2013.12.011.
149. Yoon JH, Lee JM, Han JK, et al. Shear wave elastography for liver stiffness measurement in clinical sonographic examinations: Evaluation of intraobserver reproducibility, technical failure, and unreliable stiffness measurements. *J Ultrasound Med.* 2014;33(3):437-447. doi: 10.7863/ultra.33.3.437.
150. Wang CZ, Zheng J, Huang ZP, et al. Influence of measurement depth on the stiffness assessment of healthy liver with real-time shear wave elastography. *Ultrasound Med Biol.* 2014;40(3):461-469. doi: 10.1016/j.ultrasmedbio.2013.10.021.
151. Ferraioli G, Parekh P, Levitov AB, et al. Shear wave elastography for evaluation of liver fibrosis. *J Ultrasound Med.* 2014;33(2):197-203. doi: 10.7863/ultra.33.2.197.
152. Cha SW, Jeong WK, Kim Y, et al. Nondiseased liver stiffness measured by shear wave elastography: A pilot study. *J Ultrasound Med.* 2014;33(1):53-60. doi: 10.7863/ultra.33.1.53.
153. Kutty SS, Peng Q, Danford DA, et al. Increased hepatic stiffness as consequence of high hepatic afterload in the Fontan circulation: a vascular doppler and elastography study. *Hepatology.* 2014;59(1):251-260. doi: 10.1002/hep.26631.
154. Sporea I, Grădinaru-Tașcău O, Bota S, et al. How many measurements are needed for liver stiffness assessment by 2D-shear wave elastography (2D-SWE) and which value should be used: the mean or median? *Med Ultrason.* 2013;15(4):268-272. doi: 10.11152/mu.2013.2066.154.isp2.
155. Leung VY, Shen J, Wong VW, et al. Quantitative elastography of liver fibrosis and spleen stiffness in chronic hepatitis B carriers: comparison of shear-wave elastography and transient elastography with liver biopsy correlation. *Radiology.* 2013;269(3):910-918. doi: 10.1148/radiol.13130128.
156. Grădinaru-Tașcău O, Sporea I, Bota S, et al. Does experience play a role in the ability to perform liver stiffness measurements by means of supersonic shear imaging (SSI)? *Med Ultrason.* 2013;15(3):180-183. doi: 10.11152/mu.2013.2066.153.ogt1is2.
157. Yoon JH, Lee JY, Woo HS, et al. Shear wave elastography in the evaluation of rejection or recurrent hepatitis after liver transplantation. *Eur Radiol.* 2013;23(6):1729-1737. doi: 10.1007/s00330-012-2748-z.
158. Hudson JM, Milot L, Parry C, et al. Inter- and intra-operator reliability and repeatability of shear wave elastography in the liver: A study in healthy volunteers. *Ultrasound Med Biol.* 2013;39(6):950-955. doi: 10.1016/j.ultrasmedbio.2012.12.011.
159. Arda K, Ciledag N, Aribas BK, et al. Quantitative assessment of the elasticity values of liver with shear wave ultrasonographic elastography. *Indian J Med Res.* 2013;137(5):911-915.
160. Poynard T, Munteanu M, Luckina E, et al. Liver fibrosis evaluation using real-time shear wave elastography: applicability and diagnostic performance using methods without a gold standard. *J Hepatol.* 2013;58(5):928-935. doi: 10.1016/j.jhep.2012.12.021.
161. Guibal A, Boularan C, Bruce M, et al. Evaluation of shearwave elastography for the characterisation of focal liver lesions on ultrasound. *Eur Radiol.* 2013;23(4):1138-1149. doi: 10.1007/s00330-012-2692-y.
162. Ferraioli G, Tinelli C, Dal Bello B, et al. Accuracy of real-time shear wave elastography for assessing liver fibrosis in chronic hepatitis C: A pilot study. *Hepatology.* 2012;56(6):2125-2133. doi: 10.1002/hep.25936.
163. Ferraioli G, Tinelli C, Zicchetti M, et al. Reproducibility of real-time shear wave elastography in the evaluation of liver elasticity. *Eur J Radiol.* 2012;81(11):3102-3106. doi: 10.1016/j.ejrad.2012.05.030.
164. Wang HK, Lai YC, Tseng HS, et al. Hepatic venous congestion after living donor liver transplantation: Quantitative assessment of liver stiffness using shear wave elastography—a case report. *Transplant Proc.* 2012;44(3):814-816. doi: 10.1016/j.transproceed.2012.01.035.

165. Bavu E, Gennisson JL, Couade M, et al. Noninvasive in vivo liver fibrosis evaluation using supersonic shear imaging: a clinical study on 113 hepatitis C virus patients. *Ultrasound Med Biol.* 2011;37(9):1361-1373. doi: 10.1016/j.ultrasmedbio.2011.05.016.

Abdomen

1. Karagiannakis DS, Voulgaris T, Koureta E, et al. Role of spleen stiffness measurement by 2D-shear wave elastography in ruling out the presence of high-risk varices in cirrhotic patients. *Dig Dis Sci.* 2019;64(9):2653-2660. doi: 10.1007/s10620-019-05616-4.
2. Gibiino G, Garcovich M, Ainora ME, et al. Spleen ultrasound elastography: state of the art and future directions—a systematic review. *Eur Rev Med Pharmacol Sci.* 2019;23(10):4368-4381. doi: 10.26355/eurrev_201905_17944.
3. Cho YS, Lim S, Kim Y, et al. Spleen stiffness measurement using 2-dimensional shear wave elastography: The predictors of measurability and the normal spleen stiffness value. *J Ultrasound Med.* 2019;38(2):423-431. doi: 10.1002/jum.14708.
4. Radulescu D, Peride I, Petcu LC, et al. Supersonic shear wave ultrasonography for assessing tissue stiffness in native kidney. *Ultrasound Med Biol.* 2018;44(12):2556-2568. doi: 10.1016/j.ultrasmedbio.2018.07.001.
5. Mazur R, Celmer M, Silicki J, et al. Clinical applications of spleen ultrasound elastography—a review. *J Ultrason.* 2018;18(72):37-41. doi: 10.15557/JoU.2018.0006.
6. Ma MK, Law HK, Tse KS, et al. Non-invasive assessment of kidney allograft fibrosis with shear wave elastography: A radiological-pathological correlation analysis. *Int J Urol.* 2018;25(5):450-455. doi: 10.1111/iju.13536.
7. Chen LD, Wang W, Xu JB, et al. Assessment of rectal tumors with shear-wave elastography before surgery: Comparison with endorectal US. *Radiology.* 2017;285(1):279-292. doi: 10.1148/radiol.2017162128.
8. Kuwahara T, Hirooka Y, Kawashima H, et al. Usefulness of shear wave elastography as a quantitative diagnosis of chronic pancreatitis. *J Gastroenterol Hepatol.* 2018;33(3):756-761. doi: 10.1111/jgh.13926.
9. Yoo MG, Jung DC, Oh YT, et al. Usefulness of multiparametric ultrasound for evaluating structural abnormality of transplanted kidney: Can we predict histologic abnormality on renal biopsy in advance? *AJR Am J Roentgenol.* 2017;209(3):W139-W144. doi: 10.2214/AJR.16.17397.
10. Liu X, Li N, Xu T, et al. Effect of renal perfusion and structural heterogeneity on shear wave elastography of the kidney: An in vivo and ex vivo study. *BMC Nephrol.* 2017;18(1):265. doi: 10.1186/s12882-017-0679-2.
11. Peng L, Zhong T, Fan Q, et al. Correlation analysis of renal ultrasound elastography and clinical and pathological changes in patients with chronic kidney disease. *Clin Nephrol.* 2017;87(6):293-300. doi: 10.5414/CN108866.
12. Correas JM, Anglicheau D, Gennisson JL, et al. Renal elastography. *Nephrol Ther.* 2016;12(1):S25-34. doi: 10.1016/j.nephro.2016.02.014.
13. Pawluś A, Ingot MS, Szymańska K, et al. Shear wave elastography of the spleen: Evaluation of spleen stiffness in healthy volunteers. *Abdom Radiol.* 2016;18(5):736-741. doi: 10.1016/j.aohp.2019.03.004.
14. Samir AE, Allegretti AS, Zhu Q, et al. Shear wave elastography in chronic kidney disease: A pilot experience in native kidneys. *BMC Nephrol.* 2015;16:119. doi: 10.1186/s12882-015-0120-7.
15. Moon SK, Kim SY, Cho JY, et al. Quantification of kidney fibrosis using ultrasonic shear wave elastography: experimental study with a rabbit model. *J Ultrasound Med.* 2015;34(5):869-877. doi: 10.7863/ultra.34.5.869.
16. Helfenstein C, Gennisson JL, Tanter M, et al. Effects of pressure on the shear modulus, mass and thickness of the perfused porcine kidney. *J Biomech.* 2015;48(1):30-37. doi: 10.1016/j.jbiomech.2014.11.011.
17. Cha SW, Kim IY, Kim YW. Quantitative measurement of elasticity of the appendix using shear wave elastography in patients with suspected acute appendicitis. *PLoS One.* 2014;9(7):e101292. doi: 10.1371/journal.pone.0101292.
18. Słapa RZ, Kasperlik-Załuska AA, Migda B, et al. Shear wave elastography of adrenal masses is feasible and may help to differentiate between solid and cystic lesions—an initial report. *Endokrynol Pol.* 2014;65(2):119-124. doi: 10.5603/EP.2014.0017.

19. Ternifi R, Gennisson JL, Tanter M, et al. Effects of storage temperature on the mechanical properties of porcine kidney estimated using shear wave elastography. *J Mech Behav Biomed Mater.* 2013;28:86-93. doi: 10.1016/j.jmbbm.2013.07.012.
20. Grenier N, Gennisson JL, Cornelis F, et al. Renal ultrasound elastography. *Diagn Interv Imaging.* 2013;94(5):545-550. doi:10.1016/j.diii.2012.02.003.
21. Grenier N, Poulain S, Lepreux S, et al. Quantitative elastography of renal transplants using supersonic shear imaging: A pilot study. *Eur Radiol.* 2012;22(10):2138-2146. doi: 10.1007/s00330-012-2471-9.
22. Gennisson JL, Grenier N, Combe C, et al. Supersonic shear wave elastography of in vivo pig kidney: influence of blood pressure, urinary pressure and tissue anisotropy. *Ultrasound Med Biol.* 2012;38(9):1559-1567. doi: 10.1016/j.ultrasmedbio.2012.04.013.
23. Derieppe M, Delmas Y, Gennisson JL, et al. Detection of intrarenal microstructural changes with supersonic shear wave elastography in rats. *Eur Radiol.* 2012;22(1):243-250. doi: 10.1007/s00330-011-2229-9.
24. Arda K, Ciledag N, Aktas E, et al. Quantitative assessment of normal soft-tissue elasticity using shear-wave ultrasound elastography. *AJR Am J Roentgenol.* 2011;197(3):532-536. doi: 10.2214/AJR.10.5449.

End of document

HOLOGIC.COM

Hologic Inc. All rights reserved. Hologic, SuperSonic, SuperSonic Aixplorer MACH, ShearWave, TriVu, SonicPad, and UltraFast, are trademarks and/or registered trademarks of Hologic, Inc., and or its subsidiaries in the United States and other countries. SuperSonic MACH 30 was previously known as Aixplorer MACH 30. This information is intended for medical professionals in the U.S. and other markets and it not intended as a product solicitation or promotion where such activities are prohibited. Because Hologic materials are distributed through websites, eBroadcasts and tradeshow, it is not always possible to control where such materials appear. For specific information on what products are available for sale in a particular country, please contact your local Hologic representative or write to womenshealth@Hologic.com. This is a general information tool for medical professionals and is not a complete representation of the product(s)' Instruction for Use (IFU) or Package Insert, and it is the medical professionals' responsibility to read and follow the IFU or Package Insert. The information provided may suggest a particular technique or protocol however it is the sole responsibility of the medical professional to determine which technique or protocol is appropriate. At all times, clinicians remain responsible for utilizing sound patient evaluation and selection practices, and for complying with applicable local, state, and federal rules and regulations regarding accreditation, anesthesia, reimbursement, and all other aspects of in-office procedures. In no event shall Hologic be liable for damages of any kind resulting from your use of 15/15 the information presented. All other trademarks, registered trademarks, and product names are the property of their respective owners. Views and opinions expressed herein by third parties are theirs alone and do not necessarily reflect those of Hologic. Indications for Use: The SuperSonic Imagine Aixplorer MACH® range ultrasound diagnostic systems and transducers, are intended for general purpose pulse echo ultrasound imaging, soft tissue elasticity imaging and Doppler fluid flow analysis of the human body. The Aixplorer MACH® ultrasound diagnostic systems are indicated for use in the following applications, for imaging and measurement of anatomical structures: Abdominal, Small Organs, Musculoskeletal, Superficial Musculoskeletal, Vascular, Peripheral Vascular, Intraoperative, OB-GYN, Pelvic, Pediatric, Transrectal, Transvaginal, Urology, Neonatal/Adult Cephalic and Non-invasive Cardiac. It is intended for use by licensed personnel qualified to direct the use of the medical ultrasound devices. CE certificate no. 26415, FDA cleared K180572. Contact Hologic at 1.800.442.9892 or visit www.hologic.com.
MKG.EC.337/ June 2020