

# Registry Study of 337 Bio-Absorbable 3-D Implants Marking Lumpectomy Cavity Benefit Cosmesis While Targeting Radiation

C.S. Kaufman,<sup>1</sup> S. Goyal,<sup>2</sup> M.J. Cross,<sup>3</sup> J. Barone,<sup>4</sup> K. Devisetty,<sup>5</sup> N.S. Dekhne,<sup>6</sup> J. Dilworth,<sup>6</sup> D. Edmonson,<sup>7</sup> J. Gass,<sup>7</sup> C. Graham,<sup>8</sup> R.L. Hong,<sup>9</sup> B. Patton,<sup>10</sup> R. Phillips,<sup>11</sup> S.M. Schonholz,<sup>12</sup> L.A. Smith,<sup>13</sup> L. Tafra,<sup>14</sup> A. Smith<sup>15</sup>

<sup>1</sup>University of Washington, Bellingham, Washington, <sup>2</sup>Rutgers Cancer Institute of New Jersey, New Brunswick, New Jersey, <sup>3</sup>Breast Treatment Associates, Fayetteville, Arkansas, <sup>4</sup>Exempla St. Joseph Hospital, Denver, Colorado, <sup>5</sup>Karmanos Cancer Institute, Flint, Michigan, <sup>6</sup>William Beaumont Hospital, Royal Oak, Michigan, <sup>7</sup>Women and Infants Hospital, Providence, Rhode Island, <sup>8</sup>Georgia Breast Care, Marietta, Georgia, <sup>9</sup>Virginia Hospital Center, Arlington, Virginia, <sup>10</sup>Saint Joseph Hospital, Denver, Colorado, <sup>11</sup>Metro Surgical Associates, Atlanta, Georgia, <sup>12</sup>Noble Hospital, Springfield, Massachusetts, <sup>13</sup>Linda Ann Smith, MD, Albuquerque, New Mexico, <sup>14</sup>Anne Arundel Health System, Baltimore, Maryland, <sup>15</sup>Highlands Oncology Group, Fayetteville, Arkansas

Presented at the 2017 Society of Surgical Oncology Annual Cancer Symposium in Seattle, Washington

## Abstract

**Introduction:** Oncoplastic procedures at the time of lumpectomy have become commonplace.



A 3-D bioabsorbable implant placed during lumpectomy may deliver solutions to three common problems; providing a dependable tumor bed target for radiation, providing a scaffold for oncoplastic closure resulting in better cosmesis and identifying re-excision sites after tissue rearrangement. An IRB-approved Registry started in 2012 collected 337 cases to assess these issues.

**Methods:** A bioabsorbable 3-D implant was sutured to the

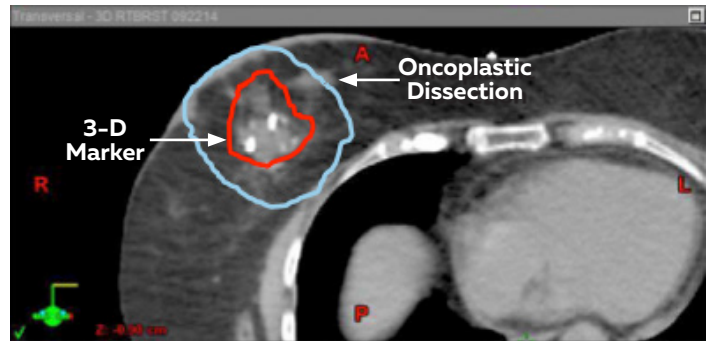
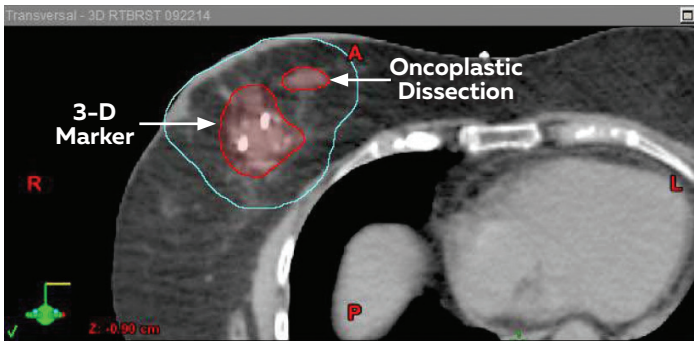
tumor excision site during lumpectomy and was utilized for planning and targeting breast irradiation. Data includes patient demographics, breast size, tumor characteristics, surgical and radiotherapy techniques, cosmesis and follow-up.

**Results:** As of September 2016, there are 337 patients from 14 centers involving 17 physicians from 12 states enrolled in the implant registry. Tumor characteristics are similar to other reports

involving early breast cancer regarding patient age, size, location, tumor histology, prognostic indicators, node positivity (12%), and location (upper outer 48%). Cancers were T-1 (56%), T-2 (18%) and DCIS (20%). In most cases, implant sizes mirrored the size of the original tumor, 2X2cm (39%) and 2X3cm (33%). The radiation oncologist verified implant as "easily seen" on CT in 92% of cases and 96% found "improved accuracy" in boost targeting and set up. Oncoplastic procedures were used in 90% of patients with 41% using the device as a scaffold for tissue support. Cosmesis was highly rated as "good" or "excellent" at 6, 12, and 24 months by surgeons (94%, 97%, 90%) and by patients (95%, 94%, 87%). The device contributed to the cosmetic benefit for each time period (78%, 80%, and 80%). See Figures.



**Conclusion:** An IRB approved Registry reports the benefits of a 3-D bioabsorbable implant placed during lumpectomy to provide a dependable target for radiation, a scaffold for oncoplastic tissue rearrangement and to enhance cosmesis over time. This report of 337 patients describes early evidence that this device may achieve multiple goals. Further collection of data over time will validate these early impressions.

## Improved Targeting Decreases Treatment Volume – Less Fibrosis

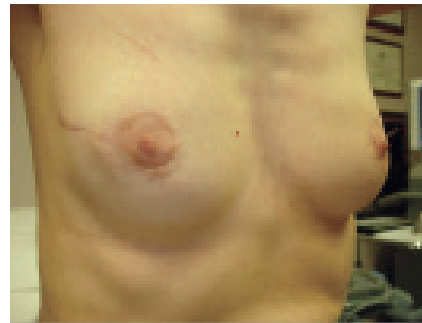
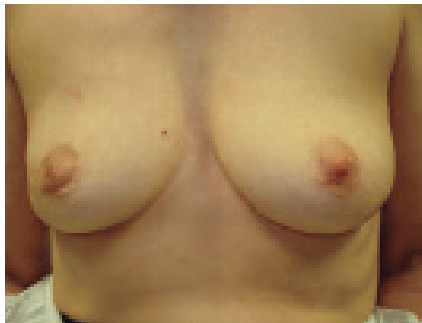


$$\text{Volume of a sphere} = \frac{4}{3}\pi r^3$$

## Breast Volume Replacement – Improved Cosmesis, Less Scarring

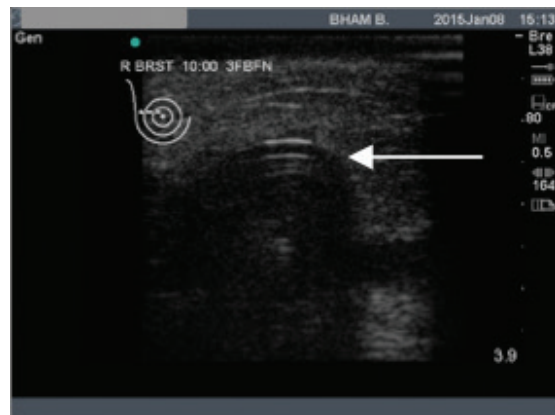
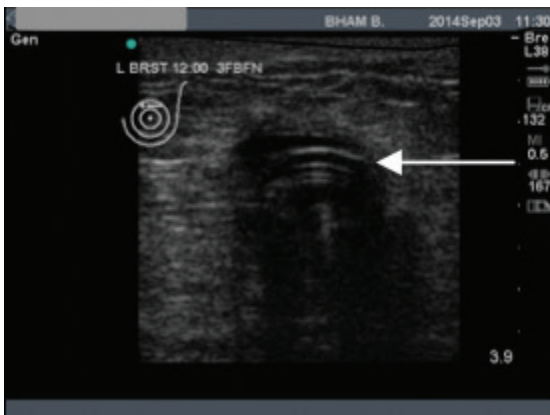


1.8cm IDC 2x3cm BZ at 1 year

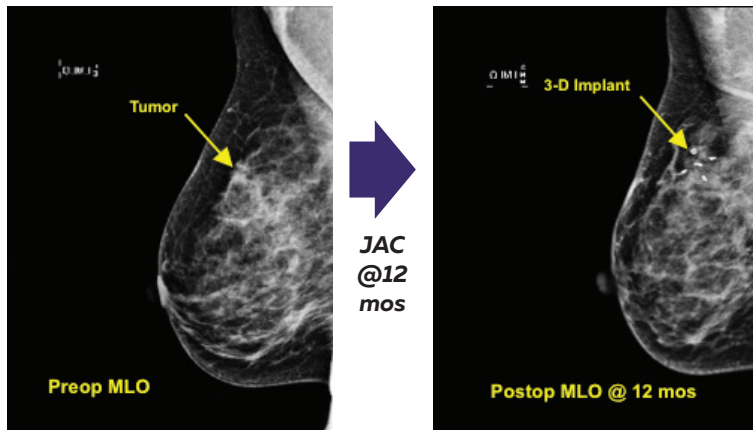


3.5cm IDC 2x3cm BZ at 1 year

## Ultrasound Visualizes the Tissue Implant (Double Arc)



# Little Fibrosis at Imaging at 6–12 Months – Dissolves Beyond 12 Months



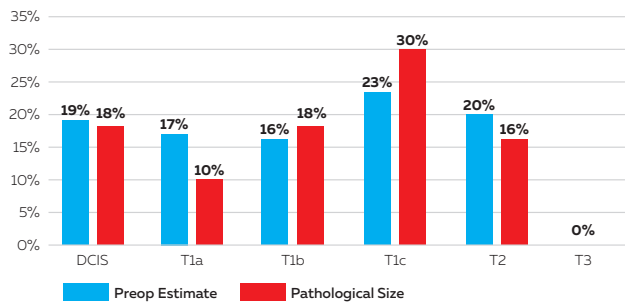
Maintains contour, fills void, little fibrosis.

## Radiation Oncologists report:

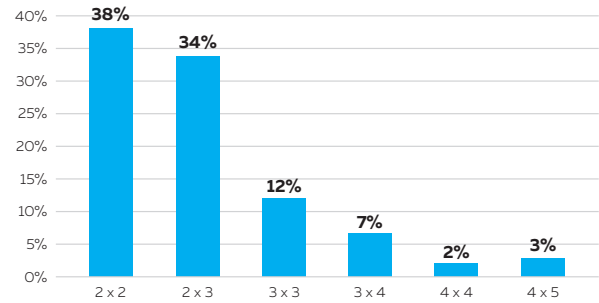
Easily seen in Rx Planning	90%
Very Useful in Rx Planning	81%
Improved Accuracy in Targeting	90%

All charts based on 443 patients

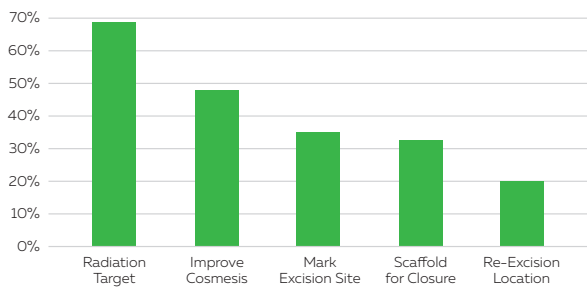
## Tumor Size



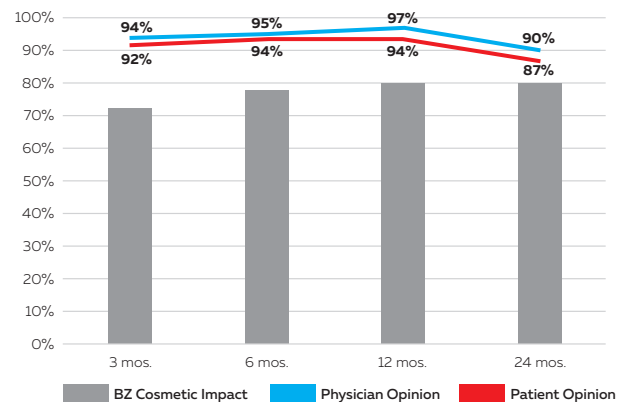
## Size Implant Used



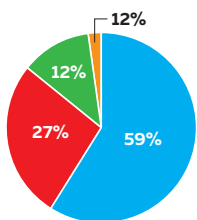
## Surgeon's Stated Reason to Use Implant



## Good to Excellent Cosmesis

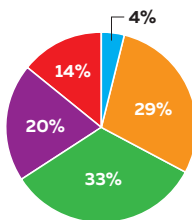


## Age Distribution



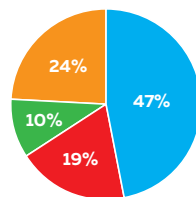
- >60 years
- 50-59 years
- 40-49 years
- <40 years

## Cup Size (%)



- A cup
- B cup
- C cup
- D cup
- >D cup

## Quadrant of Breast



- Upper Outer
- Lower Outer
- Lower Medial
- Upper Medial

## National Data

- Over 10,000 implanted over 3 years
- Over 490 patients in National Registry to follow for 36 months
- Over 400 sites using the device

## 3-D Tissue Implant Results

1. Radiotherapy Targeting
2. Visual Marker on Imaging
3. Breast Volume Replacement
4. Good/Excellent Cosmesis
5. Patient Satisfaction