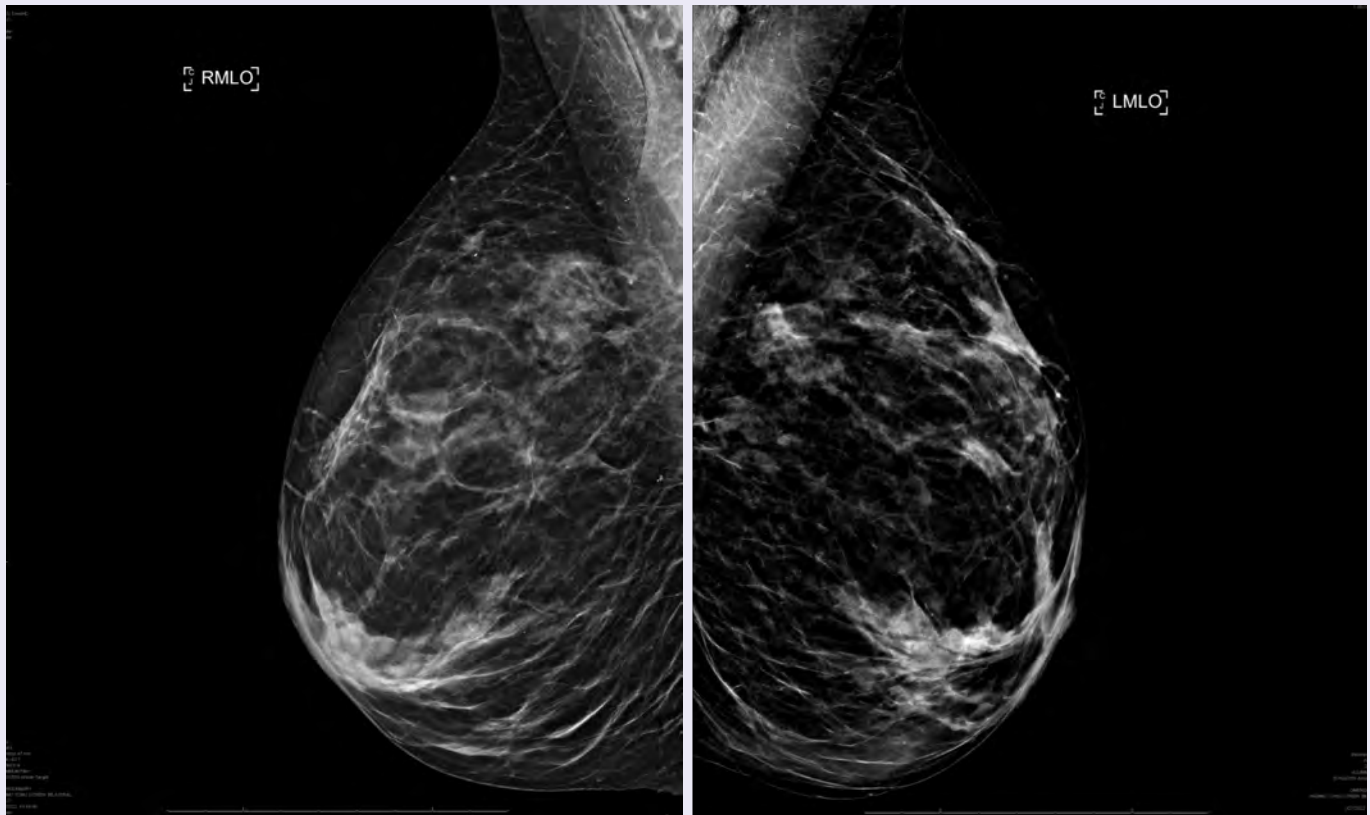


# Clinical Images of Tumark® Vision and Tumark® Conic biopsy site markers

Courtesy of Dr. Tchaiko Parris, M.D., Ph.D.

## Patient Background

- Asymptomatic 66 y.o female presents for a screening mammogram.
- There are two new asymmetries in the right breast posterior depth superior region on the MLO projection. Findings not seen on the CC projection.

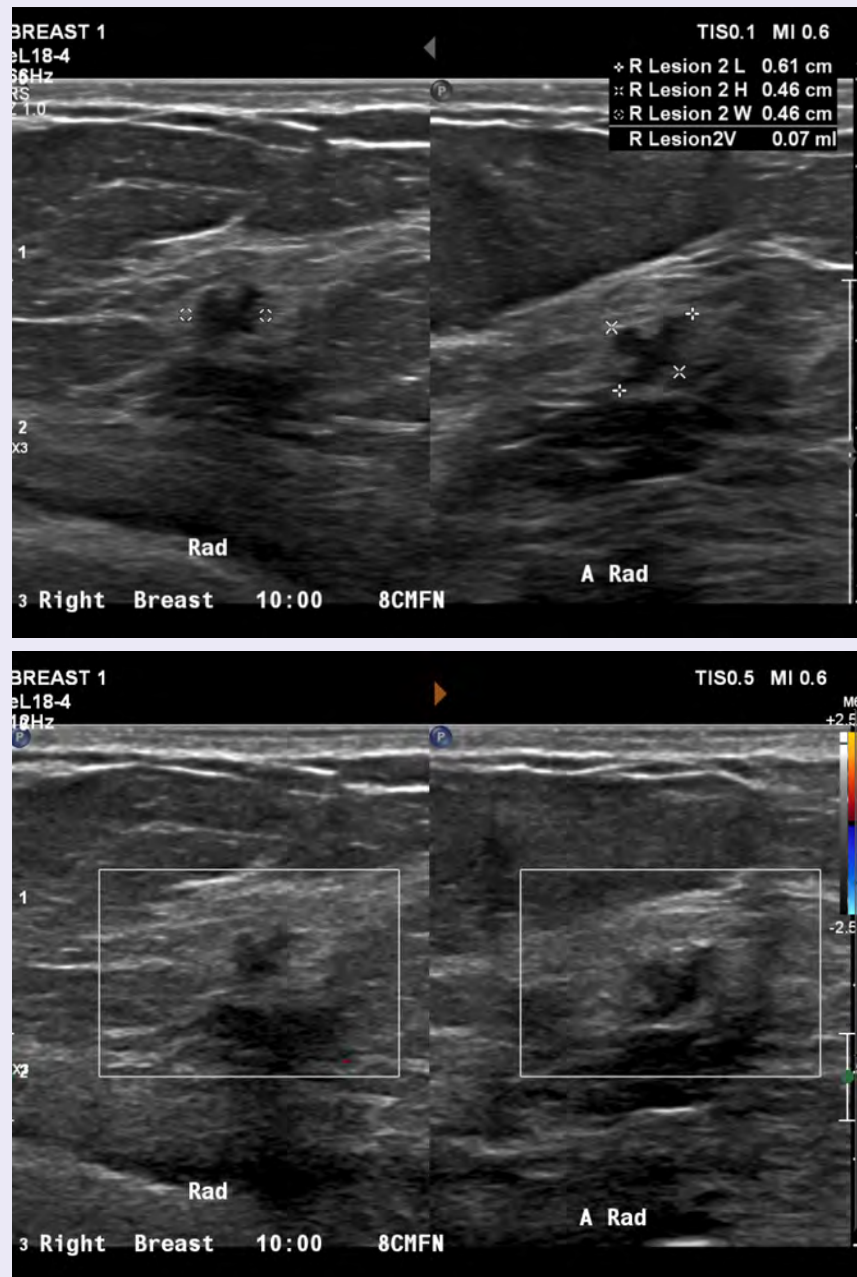


# Clinical Images of Tumark® Vision and Tumark® Conic biopsy site markers

Courtesy of Dr. Tchaiko Parris, M.D., Ph.D.

## Patient Background

- Right breast ultrasound.
- Irregular hypoechoic mass with angular margins at the 10 o'clock location.
- Measurements and color doppler

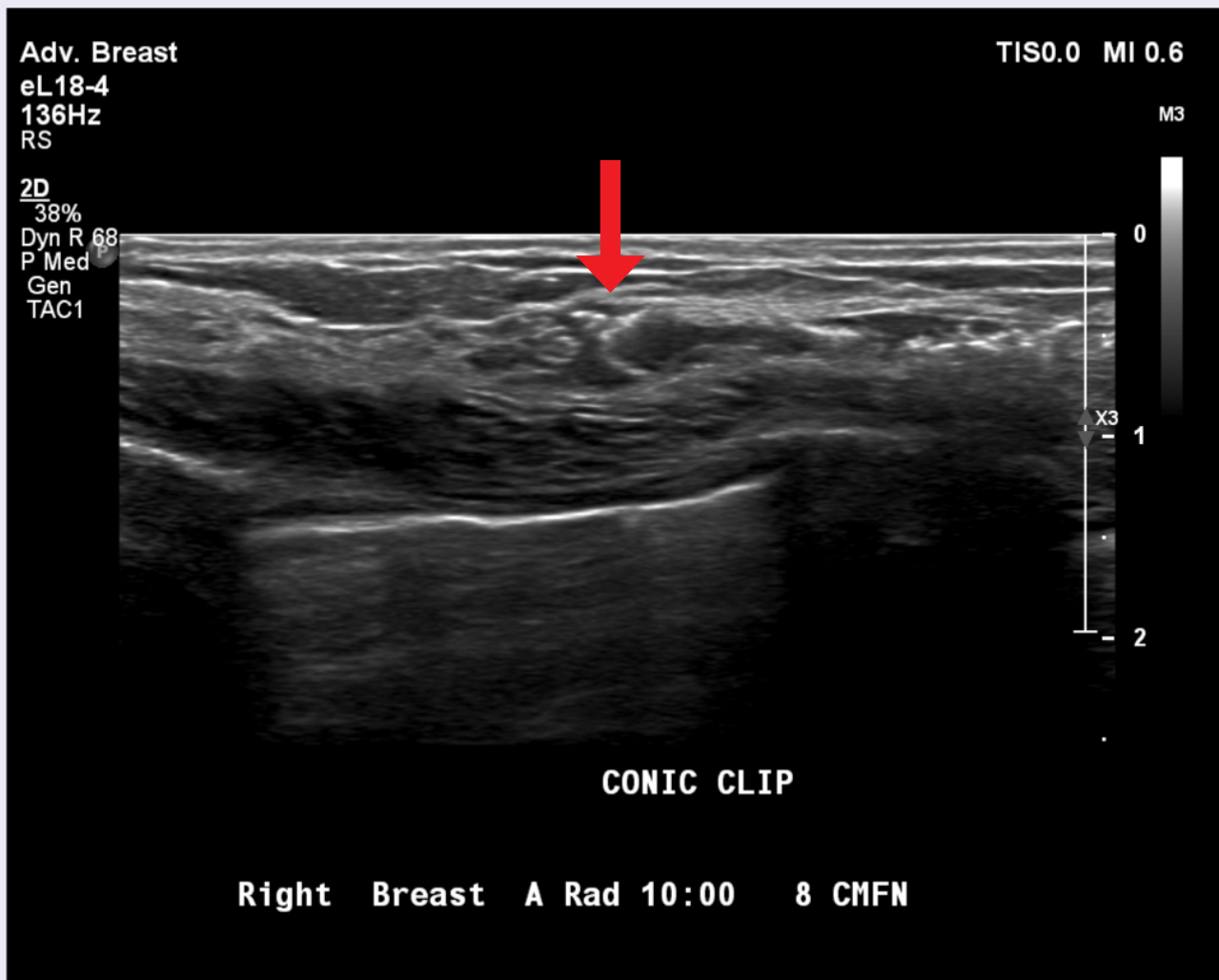


# Clinical Images of Tumark® Vision and Tumark® Conic biopsy site markers

Courtesy of Dr. Tchaiko Parris, M.D., Ph.D.

## Patient Background

- Right breast ultrasound.
- Irregular hypoechoic mass with angular margins at the 10 o'clock location
- Post clip – Tumark Conic

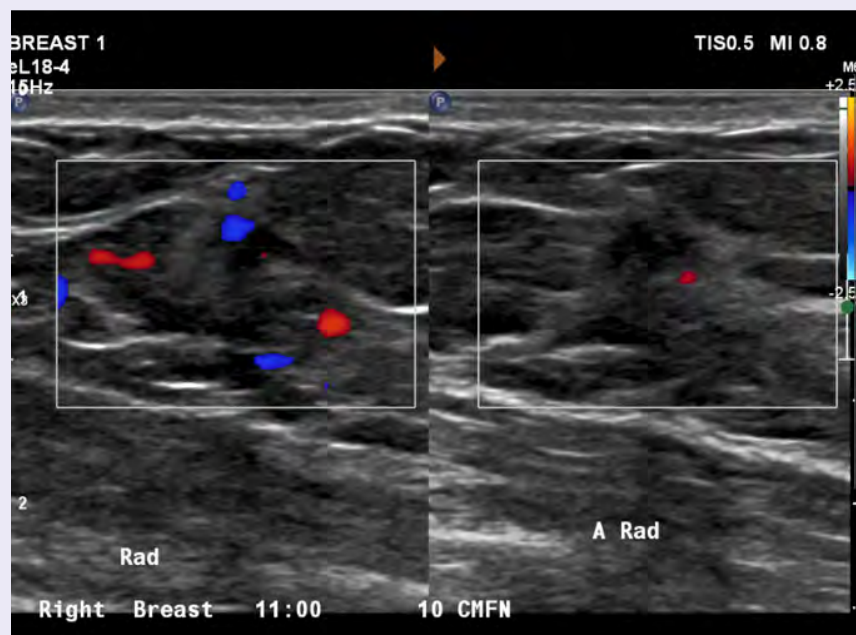
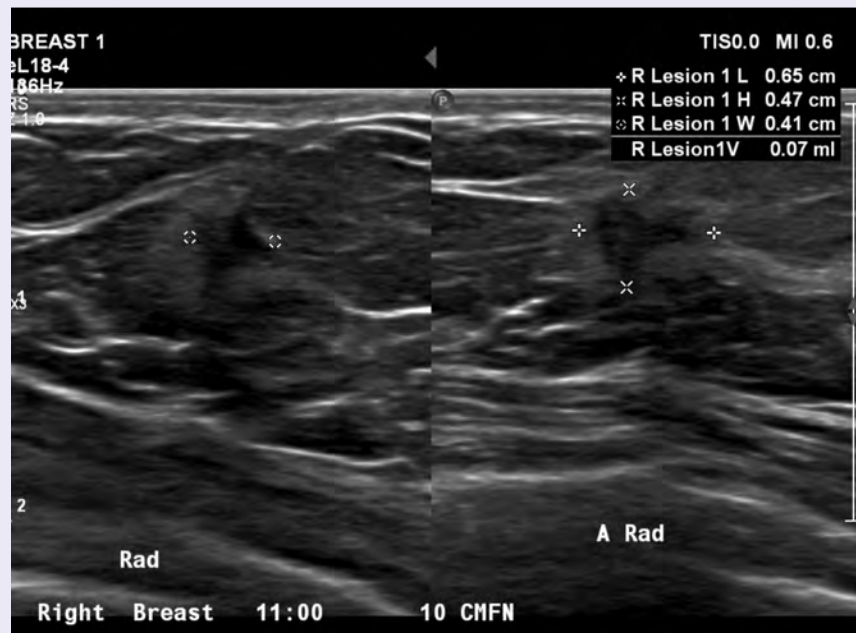


# Clinical Images of Tumark® Vision and Tumark® Conic biopsy site markers

Courtesy of Dr. Tchaiko Parris, M.D., Ph.D.

## Patient Background

- Right breast ultrasound.
- Irregular hypoechoic mass with angular margins at the 11 o'clock location.
- Measurements and color doppler

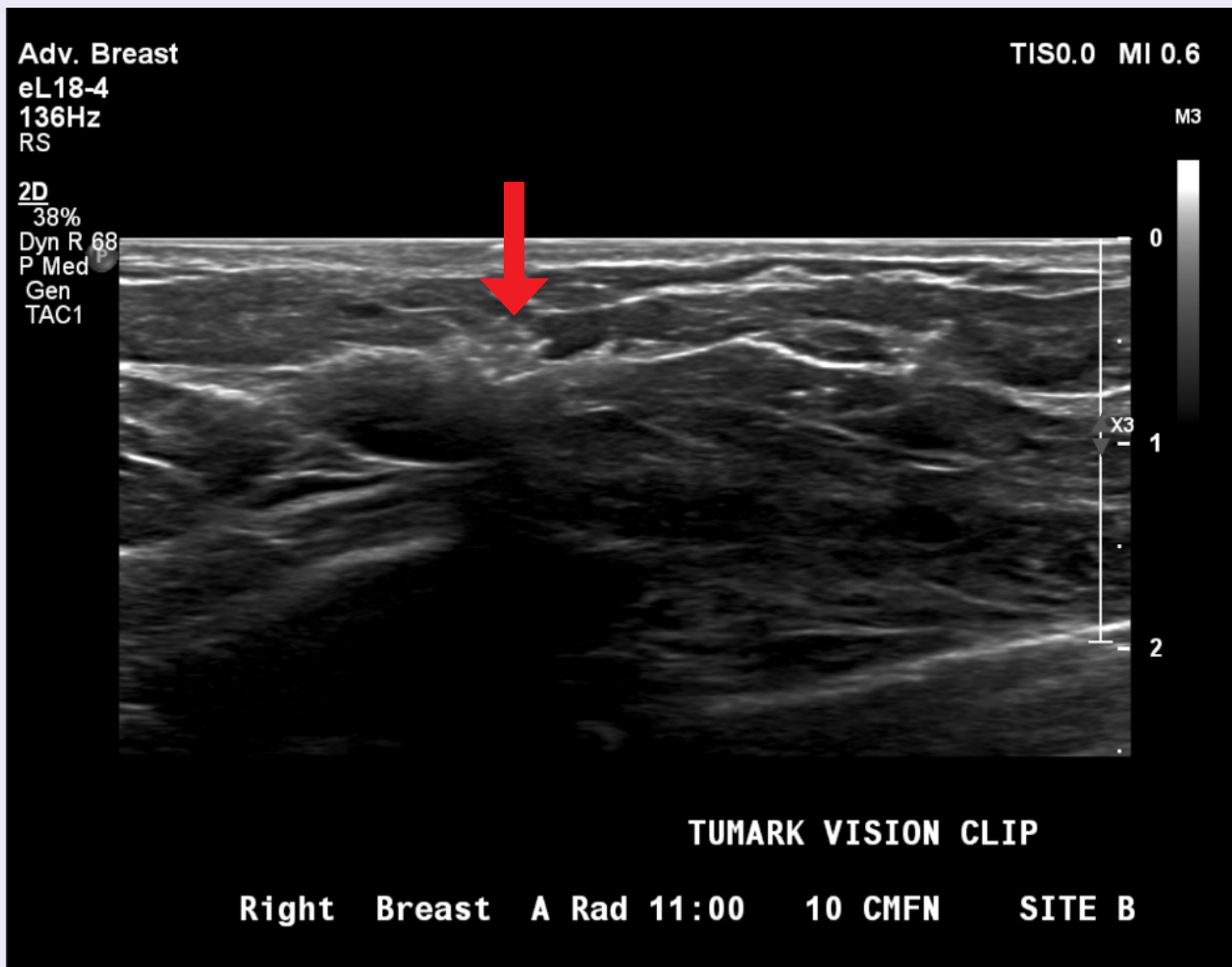

# Clinical Images of Tumark® Vision and Tumark® Conic biopsy site markers

Courtesy of Dr. Tchaiko Parris, M.D., Ph.D.

## Patient Background

- Right breast ultrasound.
- Irregular hypoechoic mass with angular margins at the 11 o'clock location
- Post clip – Tumark Vision

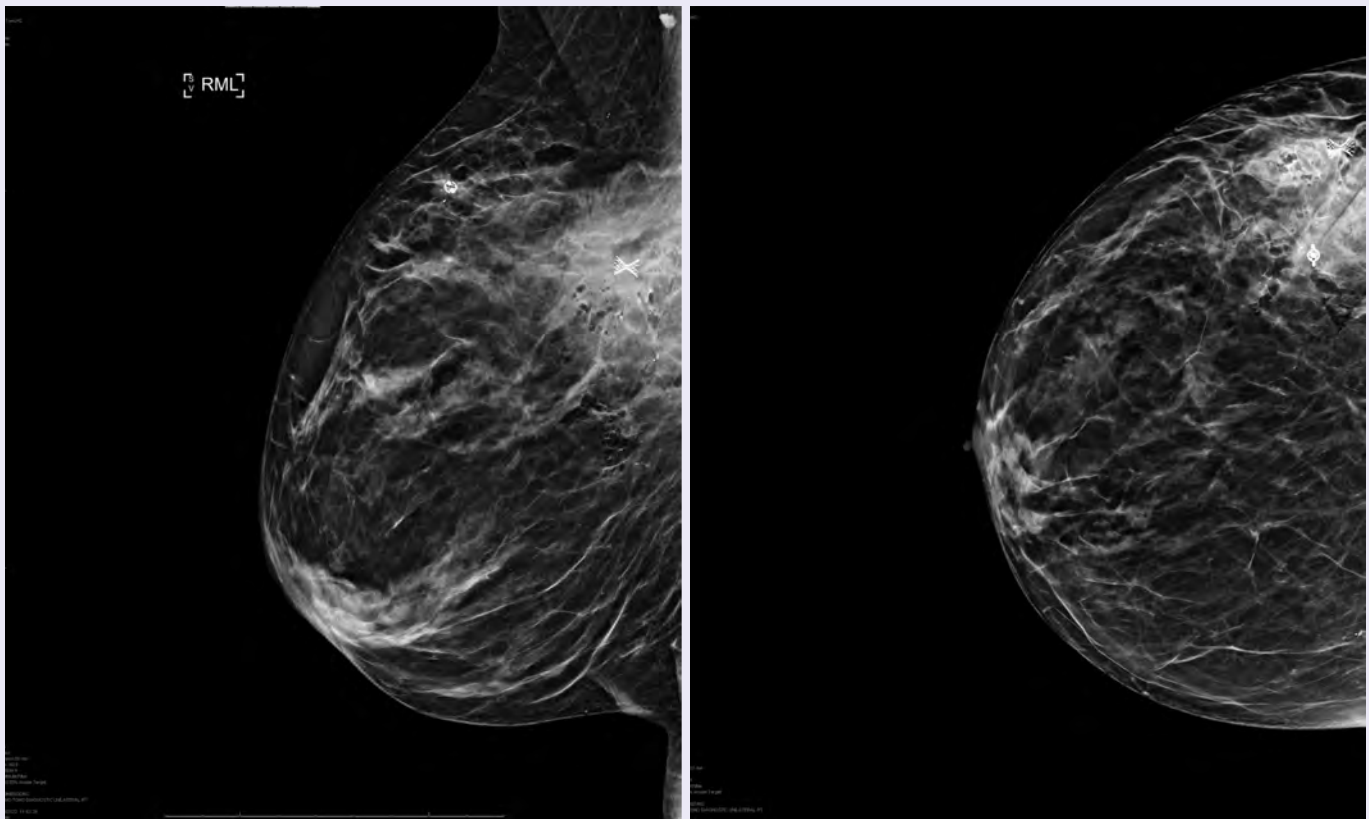


# Clinical Images of Tumark® Vision and Tumark® Conic biopsy site markers

Courtesy of Dr. Tchaiko Parris, M.D., Ph.D.

## Patient Background

- Right breast post mammogram
- Tumark Conic and Vision clips
- Pathology for both sites: Invasive ductal carcinoma grade 3 ER positive, PR negative, Ki-67 25-30% and Her2Neu by IHC 2+



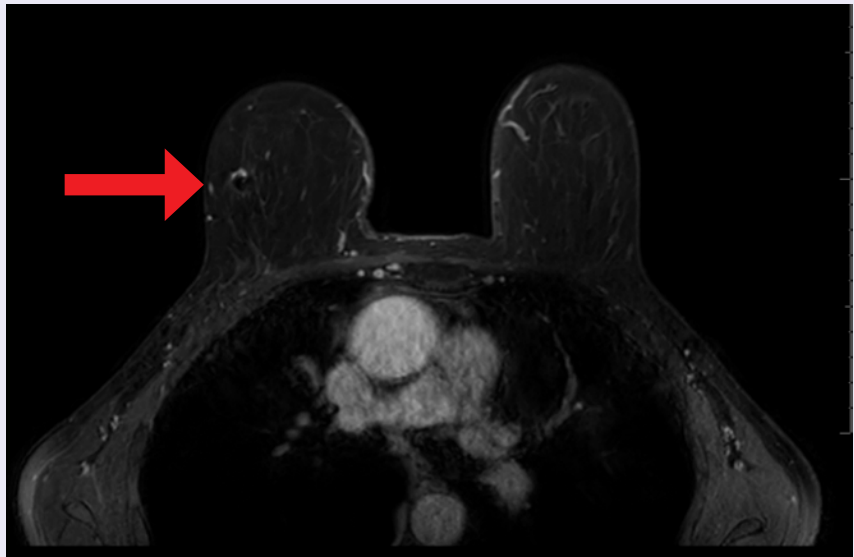


## Clinical Images of Tumark<sup>®</sup> Vision and Tumark<sup>®</sup> Conic biopsy site markers

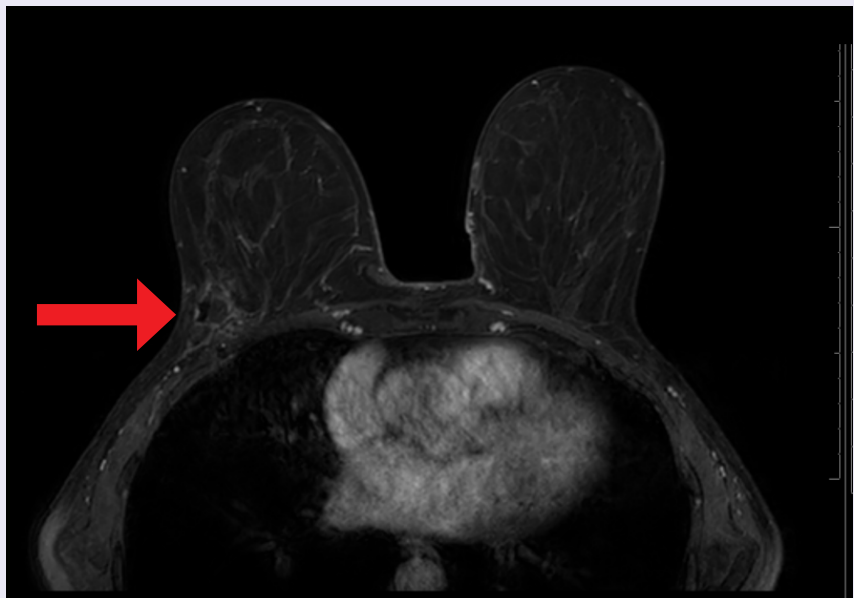
Courtesy of Dr. Tchaiko Parris, M.D., Ph.D.

### Patient Background

- Right breast MRI axial subtraction post contrast projection.
- Tumark Conic clip 10 o'clock and Tumark Vision clip 11 o'clock
- Pathology for both sites: Invasive ductal carcinoma grade 3 ER positive, PR negative, Ki-67 25-30% and Her2Neu by IHC 2+



Tumark Vision – 11 o'clock

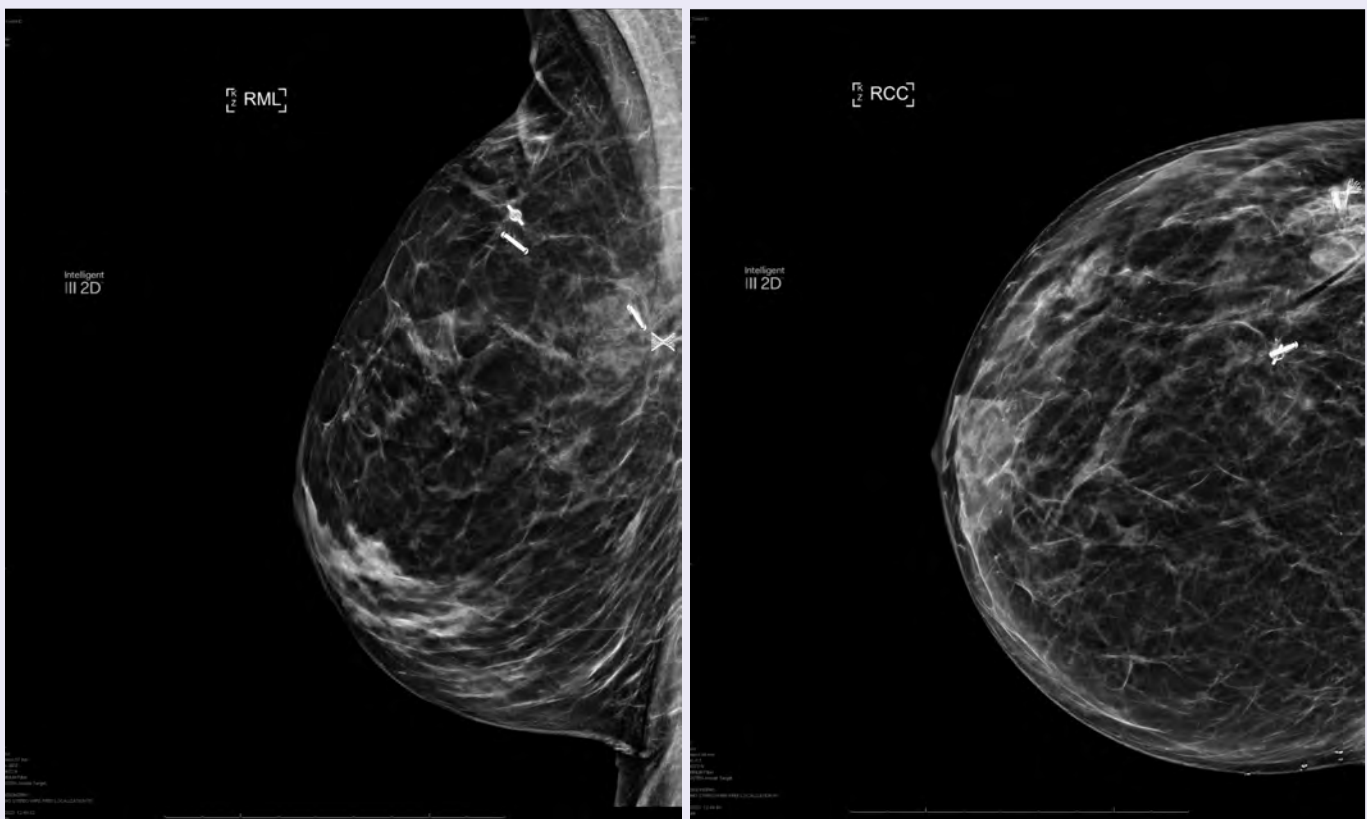


Tumark Conic – 10 o'clock

# Clinical Images of Tumark® Vision and Tumark® Conic biopsy site markers

Courtesy of Dr. Tchaiko Parris, M.D., Ph.D.

- Tumark Vision and Conic clips with the respective LOCalizer™



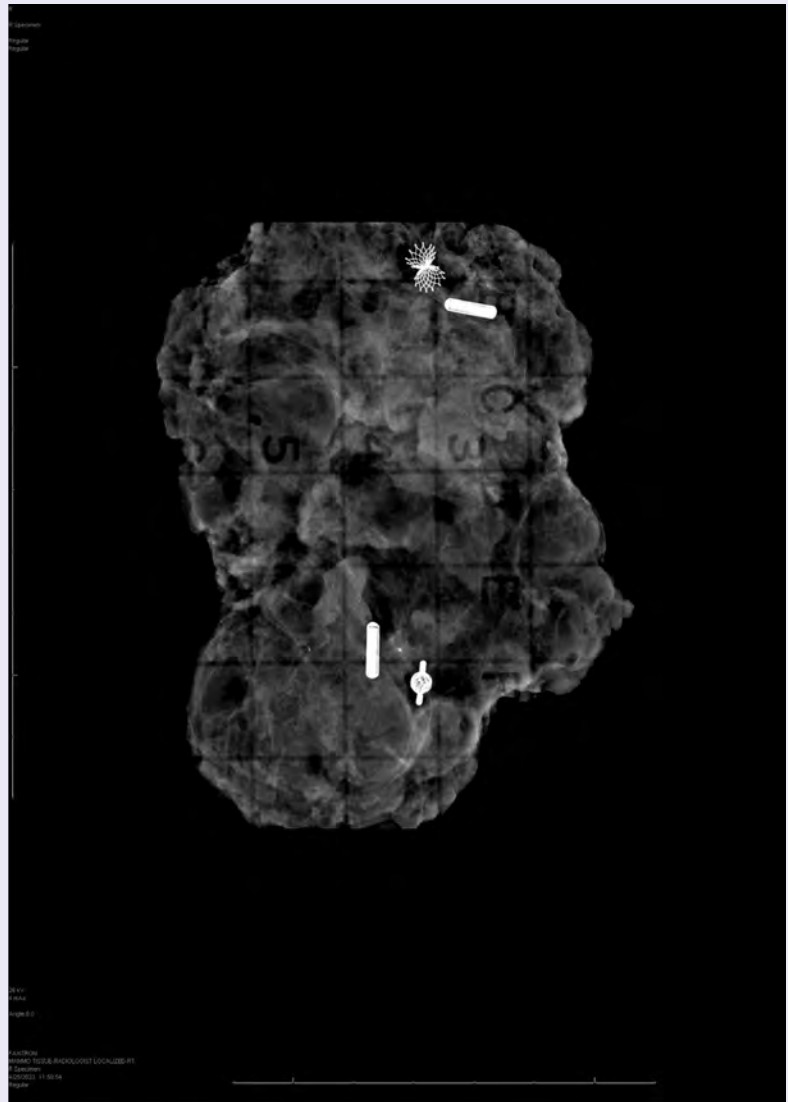


# Clinical Images of Tumark<sup>®</sup> Vision and Tumark<sup>®</sup> Conic biopsy site markers

Courtesy of Dr. Tchaiko Parris, M.D., Ph.D.

## Patient Background

- Right breast -Specimen Radiograph
- Tumark Conic and Vision Clips with LOCALizer



# Tumark<sup>®</sup>

Biopsy Site Markers

MKL-01042 ©2023 Hologic Inc. All rights reserved. Hologic, LOCALizer and Tumark and associated logos are trademarks and/or registered trademarks of Hologic, Inc., and/or its subsidiaries in the United States and/or other countries. This information is intended for medical professionals in the U.S. and other markets and is not intended as a product solicitation or promotion where such activities are prohibited. All materials, images and content are intellectual property of Hologic and may not be copied, reproduced, distributed or displayed without permission.

[www.hologic.com](http://www.hologic.com) | 1.800.442.9892