

# Tomosynthesis finds invasive lobular carcinoma not visible on 2D mammography

By Thomas S. Chang, MD,  
FACR

Dr. Chang is a Diagnostic Radiologist at Weinstein Imaging Associates in Pittsburgh, PA.

This article is intended for medical professionals and/or specific product users residing in the United States and other countries and should not be considered as a solicitation or promotion of any product or of an indication of any product that is not authorized by the laws and regulations of another country where the reader resides. This article could refer to products that are or may not be available in any particular country, and/or may not have received market clearance by a governmental regulatory body for indications and restrictions in different countries.

## Background

The interpretation of conventional 2-dimensional (2D) mammography is challenging, due to confounding overlapping structures that both mimic and hide breast cancer, especially in dense breasts.<sup>1</sup> Breast tomosynthesis, also known as 3-dimensional (3D) mammography, approved by the Food and Drug Administration (FDA) in February 2011, is an innovative technology that has been shown to overcome much of the confounding effects of tissue superimposition. Clinical studies have estimated reductions in screening recall rates of 15% to 40%.<sup>2,3</sup> Higher cancer detection rates have also been demonstrated. The Oslo Tomosynthesis Screening Trial, which included over 12,600 patients, reported detection rates that were 40% higher for invasive cancers and 27% higher for all cancers.<sup>2</sup> Better lesion-margin analysis and more accurate lesion location have also been reported.<sup>4</sup>

In a tomosynthesis scan, the x-ray tube head moves over the breast, acquiring 15 low-dose images over a 15-degree arc to produce a dataset that is then reconstructed into thin, 1-mm slices for the entire thickness of the breast. These images are viewed on a diagnostic workstation individually or in cine format. The 3D images are designed to reveal the inner architecture of the breast free of interference from superimposed tissue above and below the slice of interest. As currently required by the FDA, a screen-

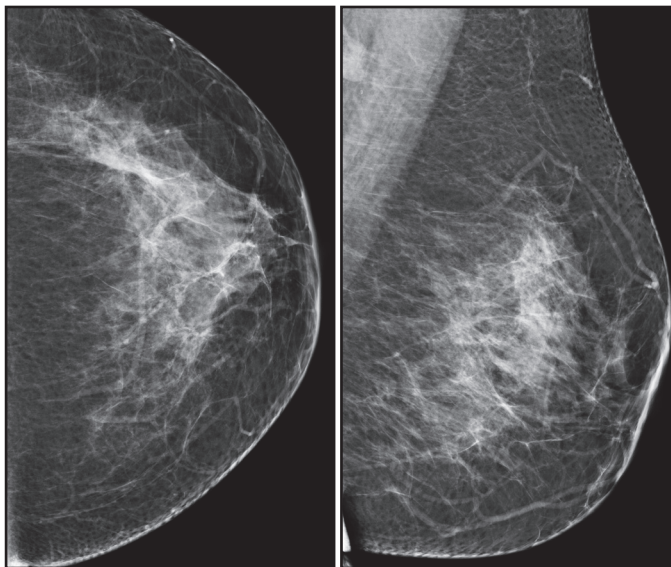
ing examination includes both the 3D dataset and the conventional 2D images. While the breast is still in compression, the 2D image is acquired immediately after the 3D sweep.

## Patient Information

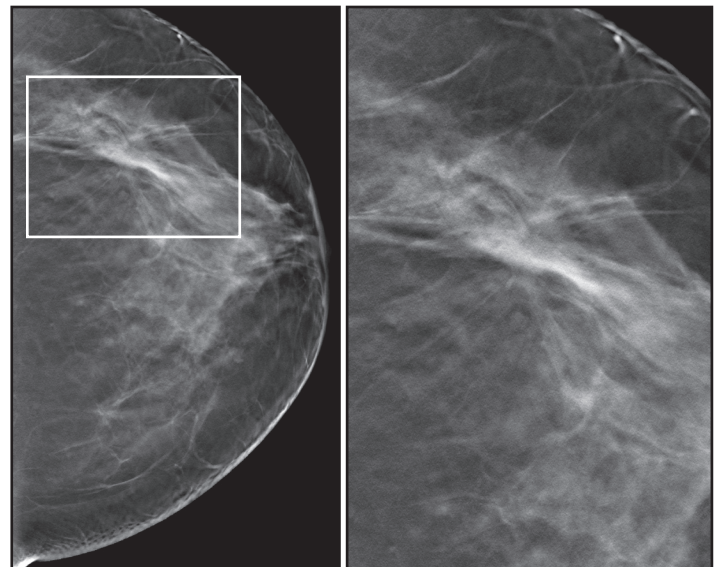
A 48-year-old asymptomatic female presented for annual screening mammography with 2D/3D imaging. Her prior mammogram had been normal 12 months previously. Family history was significant for breast cancer in her mother at age 69 and in a cousin at age 60.

## Imaging Findings

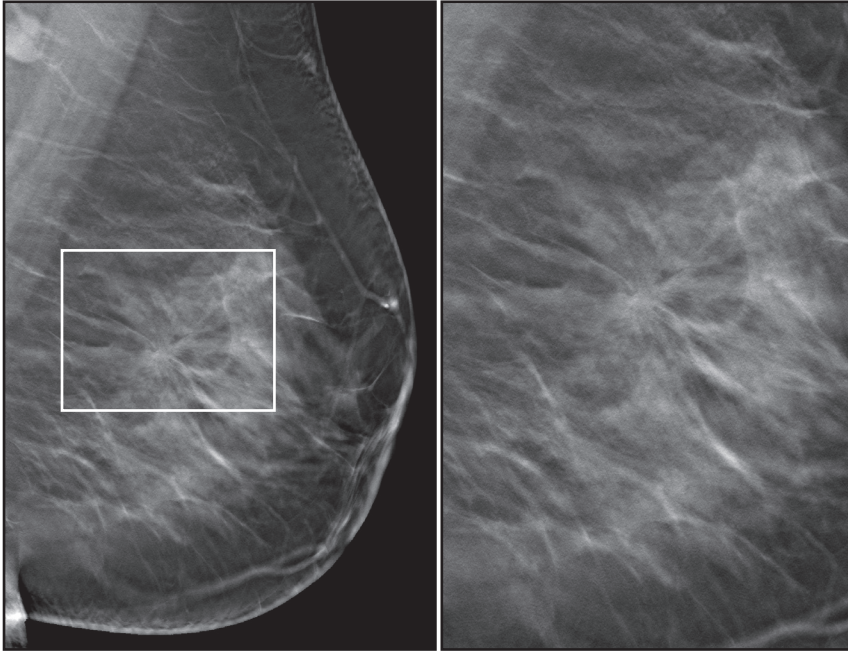
Both breasts were imaged with conventional 2D mammography and breast tomosynthesis. The breast tissue was heterogeneously dense. The 2D mammogram (Figure 1) showed no obvious suspicious findings. Mild focal asymmetry in the lateral breast on the CC view did not have a corresponding abnormality on the MLO view. Upon review of the tomosynthesis images (Figures 2 and 3), a small, spiculated mass was clearly demonstrated at the 3 o'clock position of the left breast. Ultrasonography (Figure 4) revealed a  $1.4 \times 0.7 \times 0.9$  cm irregularly-shaped, spiculated, hypoechoic, shadowing mass at the area of mammographic concern. There was no significant blood flow in the mass on color Doppler evaluation. Ultrasound-guided core biopsy of the mass was performed on the same day.



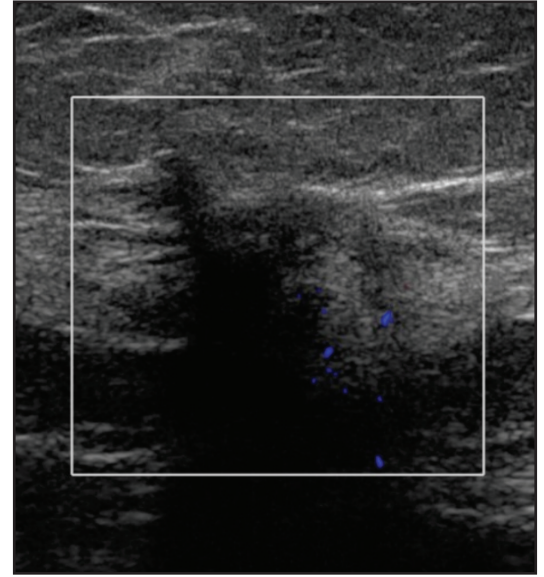
**FIGURE 1.** CC and MLO 2-dimensional mammographic images of the left breast reveal heterogeneously dense breast tissue, but no obvious suspicious findings. Mild focal asymmetry in the lateral breast on the CC view does not have a corresponding finding on the MLO view.



**FIGURE 2.** CC tomosynthesis image and a close-up of the area-of-interest clearly reveal a spiculated mass in the lateral breast.



**Figure 3.** MLO tomosynthesis image and a close-up of the area-of-interest show that the main feature of this invasive lobular carcinoma is the presence of long radiating spicules, which extend for a distance of about 5 cm. By comparison, the central mass is relatively small.



**FIGURE 4.** Color Doppler sagittal sonographic image at the 3 o'clock position of the left breast reveals a 1.4-cm irregularly shaped, ill-defined, markedly hypoechoic, shadowing mass with no demonstrable internal blood flow. On surgical pathology, the invasive lobular carcinoma proved to be 5 cm in size.

## Diagnosis

The patient was diagnosed with clinical stage 3 invasive lobular carcinoma. The results of the core biopsy were invasive lobular carcinoma, nuclear grade 2, with focal lymphovascular invasion and lobular carcinoma *in situ*, nuclear grade 1. Nottingham score was 7/9. Estrogen and progesterone receptors were positive. Her2 was negative. Ki-67 proliferative index was low at 10%.

## Treatment

The patient opted to undergo a mastectomy. The surgical pathology results were 5.0 cm invasive carcinoma, predominately classical lobular type (> 95%) with clear margins. Nottingham score was 6/9. Five sentinel lymph nodes were negative for metastatic disease.

## Discussion

This case illustrates the fundamental impact breast tomosynthesis can provide in the detection of cancer over its 2D counterpart. In this case, the 2D images showed mild, nonspecific focal asymmetry on only the CC view, which is one of the ways lobular carcinoma can be present when there are no other findings to support the presence of a suspicious mass. Tomosynthesis overcame two challenges for 2D mammography: obscuration of suspicious findings by overlapping dense parenchyma and the detection of invasive lobular carcinoma, which is often difficult to detect because of its hallmark single-file growth pattern. It not only showed a small central mass but also highlighted the mass with radiating spicules, thereby increasing diagnostic confidence.

The detection by tomosynthesis of this otherwise occult lobular carcinoma at an earlier stage improved the chance for this patient's complete cure and survival.

This case also demonstrates the frequent underestimation of the size of invasive lobular carcinomas by 2D mammography and sonography. 2D mammography failed to demonstrate the suspicious mass; in retrospect, a few subtle radiating lines are visible through the surrounding tissue, but these could not be appreciated prospectively. The mass's sonographic size of 1.4 cm was significantly smaller than its true size of 5.0 cm. Although the size of the central mass on tomosynthesis was < 1 cm, tomosynthesis permitted exquisite visualization of the spiculations, which extended for almost 5 cm and approximated the carcinoma's true size.

## Conclusion

In just 6 months of use in our practice, breast tomosynthesis has proven its value by not only permitting detection of otherwise occult breast cancers but also by reducing the need for additional mammographic views. In short, both sensitivity and specificity have improved.

The use of tomosynthesis increases a radiologist's accuracy and confidence in screening and diagnostic applications. It provides improved characterization of lesion margins and better visualization of lesions, especially in dense breasts. Breast tomosynthesis will no doubt become the standard of care in breast cancer screening.

## References

1. Kolb T, Lichy J, Newhouse J. Comparison of the performance of screening mammography, physical examination and breast ultrasound and evaluation of factors that influence them: An analysis of 27,825 patient evaluations. *Radiology*. 2002;225:165-175.
2. Skaane P, Bandos A, Gullien R, et al. Comparison of digital mammography alone and digital mammography plus tomosynthesis in a population-based screening program. *Radiology*. 2013 Jan 7. [Epub ahead of print].
3. Philpotts L, Raghu M, Durand M, et al. Initial experience with digital breast tomosynthesis in screening mammography. ARRS 2012, Scientific Session 22 – Breast Imaging: Screening/Emerging Technologies.
4. Zuley ML, Bandos AI, Ganott MA, et al. Digital breast tomosynthesis versus supplemental diagnostic mammographic views for evaluation of noncalcified breast lesions. *Radiology*. 2013;266:89-95. doi: 10.1148/radiol.12120552.

The views and opinions expressed in this clinical case review are the opinions of the author and do not necessarily reflect the views and opinions of the sponsoring company.