
The Principles of Contrast Mammography

Andrew Smith, Ph.D.

Vice President – Imaging Science, Hologic

Introduction

Multiple clinical studies have demonstrated that the use of screening mammography reduces mortality from breast cancer.^{1,2,3} The efficacy of mammography depends upon the ability to identify cancers based on the differing absorption of x-rays in cancerous tissue compared to adipose and glandular tissue. In mammography cancers often appear 'white', similar to normal glandular tissue, making cancer detection challenging, particularly in denser breasts with large areas of fibroglandular structures. Breast tomosynthesis, or 3D mammography, has been shown to offer advantages in improving both cancer detection and reducing false positives, through the reduction of superimposed tissue.⁴ Both conventional mammography and tomosynthesis are used to evaluate lesion morphology, or shape.

Imaging a contrast agent that has preferential uptake in regions of increased vascularity provides physiological information that may complement the morphological information obtained through mammography or tomosynthesis. This concept is the cornerstone for the use of well-known Gd-MRI breast imaging.⁵ It has been proposed that the use of a standard iodinated CT contrast agent and using x-ray imaging might also give functional information and have preferential uptake in breast cancers.⁶ Early studies using iodine agents tried two basic approaches: dual energy imaging⁷ and background subtraction.⁸ In dual energy imaging, two images are generated in rapid temporal succession from two different x-ray energies and are subtracted to enhance the visibility of the iodine. In background subtraction, an image is acquired before contrast injection and then it is subtracted from subsequent images taken after injection, in some cases minutes after the initial image. The majority of development initiatives to date have used the dual energy approach, as it offers certain advantages such as reduced sensitivity to patient motion and the improved/facilitated ability to perform bilateral examinations.

What is Contrast Mammography?

Contrast mammography refers to the imaging of an iodinated contrast agent using mammographic x-ray imaging equipment. The common acronym used is CE, which refers to Contrast Enhanced imaging. The contrast agents used are the ones typically employed in standard CT examinations. Contrast mammography can be done using 2D imaging, 3D imaging, or a combination of 2D and 3D imaging. In this paper, we will refer to 2D contrast imaging as CE2D (contrast enhanced 2D). 3D contrast imaging (CE3D), where a 3D image of the contrast agent is obtained, is not commercially available at this time. There is also a hybrid imaging approach, CE2D + 3D, where the contrast enhanced image is acquired using 2D imaging, and in addition there is a co-registered 3D image set that does not show the contrast uptake but that can be used to localize, and visualize in 3D, lesions found in the CE2D image.

Why is Contrast Mammography Useful?

Contrast mammography is useful because the contrast agent has been shown to accumulate preferentially in lesions that are metabolically active. It therefore can be used to identify lesions and potential malignancies. Because the contrast agent accumulates based on local breast physiology, images of the contrast agent offer information complementary to the strictly morphological image obtained using x-ray mammography. Additionally, the imaging of the contrast agent is mostly unaffected by dense breast tissue, so contrast mammography can be useful in dense breasts, where the performance of conventional imaging degrades.

How Does Contrast Mammography Work?

For tumors to grow, they need a blood supply, and capillary growth to deliver the blood. Rapidly growing tumors cause poorly differentiated vessels to be created. These vessels can in turn leak, and when the contrast agent is circulated

through the blood, it leaks from vessels into the extracellular space and accumulates in the tumor with sufficient concentration to allow x-ray imaging of its distribution.

How is the Contrast Agent Imaged?

The absolute concentration of the contrast agent in breast tissue is very low, even in a large malignant tumor. If a normal mammographic x-ray exposure is made after administration of the contrast agent, it is difficult to see any enhancement due to the presence of the contrast agent in the breast, because the amount of iodine is very small. Special imaging techniques are employed to enhance the imaging of the contrast agent. Dual energy imaging is used, working on the principle that the iodine in the contrast agent absorbs x-rays differently at different energies compared to normal breast tissue. In dual energy imaging, two exposures are made to obtain one low energy image and one high energy image.

The low energy image is a standard mammographic image acquired using the same kV ranges (28-33) and x-ray filters (Rh and Ag) commonly used in mammography. The

second exposure, the high energy image, is made at a high kV, typically 45-49 kV and commonly employs a copper filter. The x-ray energies of the low energy exposure are below the 'k-edge' of iodine (33 keV), and because of this the x-rays are not stopped by the iodine; therefore this low energy image contains only the breast parenchyma structures. The x-ray energies of the high energy exposure are above the k-edge and x-rays are effectively stopped in the iodine, thus resulting in an image which contains both the breast parenchyma and the iodine concentrations, comingled together.

The final resultant image is a subtraction of the two images. The subtraction removes the breast parenchyma and adipose tissue (which are present in both the low and high energy images) and leaves an image which consists primarily of the relative distribution of iodine in the breast.

When Is Contrast Mammography Used?

As a general guideline, contrast enhanced mammography is used as an adjunct following mammography and/or ultrasound examinations to localize a known or suspected

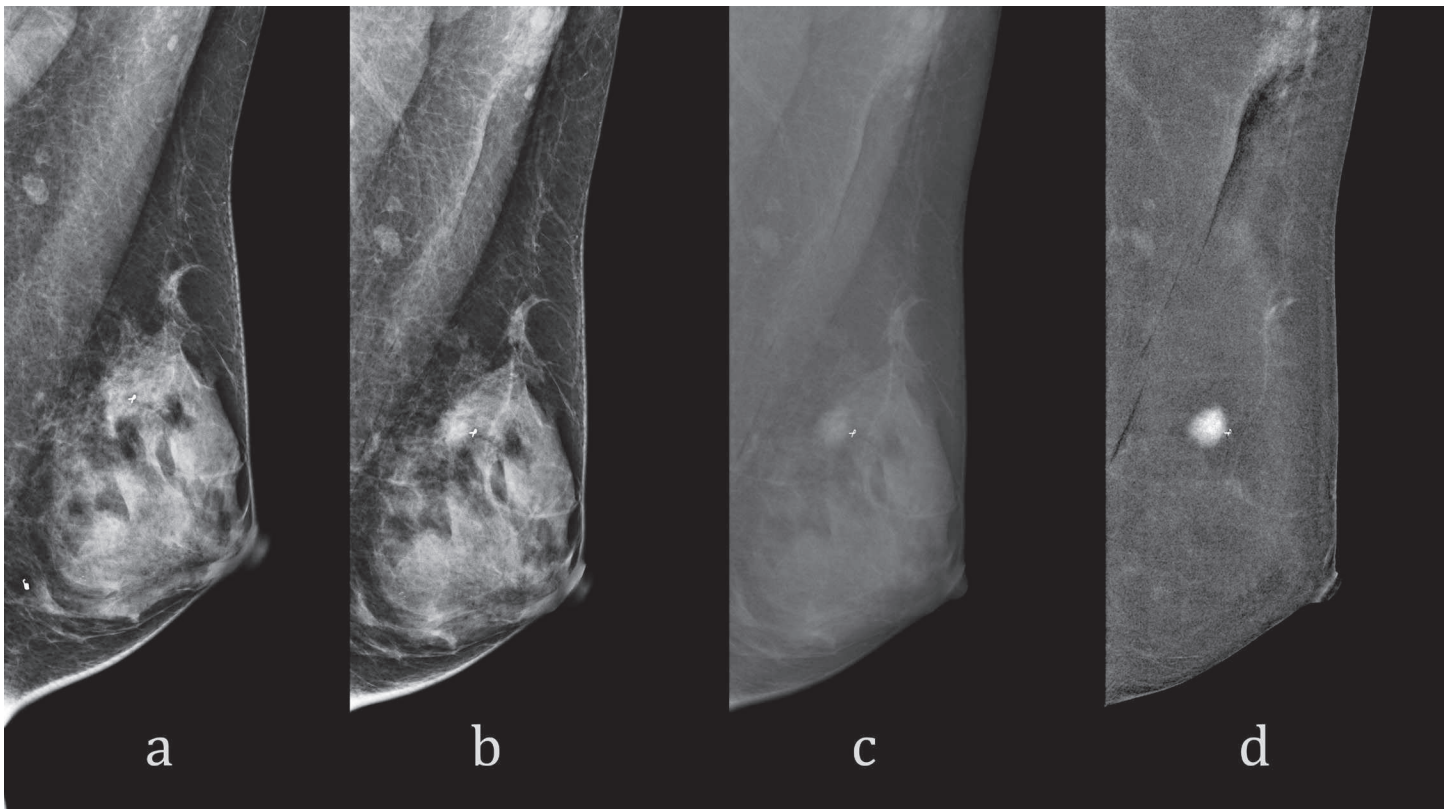


Figure 1. The low energy mammograms pre-injection (a) and post-injection (b) look almost identical, as the contrast uptake is not easily distinguished. The high energy mammogram (c) shows the lesion, as well as the breast parenchyma, but both at low contrast due to the high kV of the exposure. The final dual-energy subtracted image (d) removes most of the parenchyma and clearly shows the iodine uptake in the single isolated lesion.

lesion. Iodine contrast agents behave similarly to the gadolinium contrast agents employed in breast MRI imaging.⁹ Because of this, it has been proposed that CE imaging be used in the same clinical indications as breast MRI.¹⁰ Additionally, it may be useful in a subset of women who cannot undergo MRI imaging for a variety of reasons, such as claustrophobia.

The potential clinical uses of breast MRI, and therefore for contrast mammography, are to:

- Evaluate breasts that are difficult to interpret with mammography
- Identify potential undetected malignancies
- Image patients contraindicated for MRI
- Monitor effectiveness of drug therapy
- Evaluate extent of disease

As discussed by Lobbes in his paper, these applications for contrast mammography are at this time speculative, and research is needed to determine the efficacy of the technique.

Clinical Performance of Contrast Mammography

A number of scientific papers and presentations have looked at the performance of contrast mammography. It has been compared to mammography, ultrasound, and MRI. Dromain found CE2D+2D+US to be superior in diagnostic accuracy compared to 2D+US alone.¹¹ Fallenberg concluded that both CE2D and MRI had similar sensitivity in breast cancer detection, and both were superior to 2D.¹² Jochelson reported that CE2D has approximately similar sensitivity compared to MRI in the detection of breast cancer and is more specific in identifying additional foci in the ipsilateral breast.¹³ Lobbes looked at the performance of CE2D in women recalled from screening, and found that CE2D increased the diagnostic performance of conventional 2D imaging.¹⁴

While no commercial systems are available employing three-dimensional contrast imaging (CE3D) some researchers have investigated this possibility. Chen¹⁵ and Carton¹⁶ presented early work on CE3D. More recently, and in a larger study, Chou¹⁷ found that CE3D (along with CE2D and 2D and 3D) had similar clinical performance to Gd-MRI when measured using ROC curve area, and that both modalities detected all the invasive cancers in the study of 102 women. For non-invasive cancer, calcifications, and architectural distortions, contrast enhancement in CE3D imaging had similar or better diagnostic sensitivity when compared to Gd-MRI.

Comparison to MRI

In addition to the clinical performance reported above, a comparison of the two modalities can be made based on equipment differences. CE may be a lower cost procedure, because the system cost is lower, and the procedure time is shorter. Other possible advantages of CE include easier access to the equipment, particularly at sites with heavy MRI utilization, and system flexibility in that the same mammography system can be used if desired for high volume screening, diagnostic work ups, biopsy, and the contrast procedure. There are advantages of MRI relative to CE imaging, including acceptance of MRI as the current standard of care, the ability of MRI to image both breasts more easily than CE imaging, and the opportunity to measure tracer kinetics with MRI.

Some important advantages and disadvantages of each procedure are shown in the following chart:

| Comparison of MRI to CE Imaging | MRI with Gd contrast agent | X-ray CE with Iodine contrast agent |
|--|----------------------------|-------------------------------------|
| Standard of care | • | |
| Image both breasts in one acquisition | • | |
| Easy to measure tracer kinetics | • | |
| Uses contrast agent | • | • |
| Risk of adverse reaction to the contrast agent | • | • |
| Image both breasts in one injection | • | • |
| Equipment costs < \$1 million | | • |
| Short procedure time | | • |
| Imaging of microcalcifications ^{18*} | | • |

There are contraindications to both Gd-MRI and to CE mammography, including allergic reactions to the Gd and Iodine contrast media. In addition, certain contraindications to MRI imaging may make a contrast procedure performed on a CE mammography system a feasible alternative. A comparison of some contraindications for these procedures is listed below:

| Contraindications | MRI with Gd contrast agent | X-ray CE with Iodine contrast agent |
|--|----------------------------|-------------------------------------|
| Allergy to contrast media | • | • |
| Claustrophobia | • | |
| Metallic/electronic implants; shrapnel | • | |
| Unable to lie prone | • | |

The Iodine Contrast Agent

Contrast enhanced mammography uses standard CT non-ionic iodine contrast media. Some CT iodinated contrast agents are Iobitridol (Xenetix), Iopamidol (Isovue), Iohexol (Omnipaque), Iopromide (Ultravist), and Iodixanol (Visipaque).¹⁹

The use of iodine contrast media comes with the risk of side effects, as does the use of Gd contrast media.²⁰ Both Gadolinium and Iodine contrast media have reported a risk of death, which while extremely rare, does occur, with Gd reporting the frequency is 1/100,000 procedures and iodine 0.9/100,000. In terms of severe reactions, the frequency for Gd is 15/100,000 and for iodine 157/100,000. Standard precautions need to be taken to assess proper renal sufficiency for the procedure. No publications on contrast mammography have reported either a severe reaction or death.

Clinical Protocol

Users of contrast mammography have reported that the contrast media is administered via an intravenous injection (often 1.5 ml of media per kg body weight) of non-ionic contrast having a concentration of 300-370 mg/ml of iodine²¹ Conspicuity of lesions was subjectively improved with the higher iodine concentration.²² The injection is given using a power injector at a nominal rate of 3 ml/sec, so for a 67 kg (147 lb) woman there might be 100 ml of contrast injected in about 33 seconds. The woman can be seated during the injection, and her breasts are not under compression during the injection, to facilitate blood flow into the breast.

The appropriate left or right breast is compressed into the desired projection such as CC or MLO approximately

two minutes after the start of the contrast injection, and the first dual energy acquisition is performed. During the optimal imaging window of approximately 2 to 8 minutes post injection, additional projections of the same breast can be acquired and/or images of the other breast may be taken. The breast is compressed in the standard way for each dual energy exposure – proper compression is required – but the breast can be uncompressed between exposures. Commonly, both CC and MLO imaging are performed for both breasts. The order of breasts and projections is determined by the site, and depends upon the clinical protocol, for example, if the examination is mainly focused on the left breast then it may be appropriate to image the left breast first, when the contrast agent has its highest concentration.

A recommended window for the contrast imaging is shown in the figure below. The start time for the imaging window is commonly given as 2 minutes following initiation of the injection, and the end time is perhaps 8 minutes following injection start. This gives approximately 6 minutes in which to acquire the desired views. Similarly to Gd behavior in MRI imaging, as time progresses the visibility of lesions may decrease due to wash out and to background enhancement.

The imaging results in both a low energy mammogram, which is a normal mammogram, and the contrast-enhanced mammogram. There is typically no need to perform pre-contrast images, either 2D or 3D, because the post-contrast low energy 2D or 3D images have been determined to be acceptable replacements for the pre-contrast images.²³

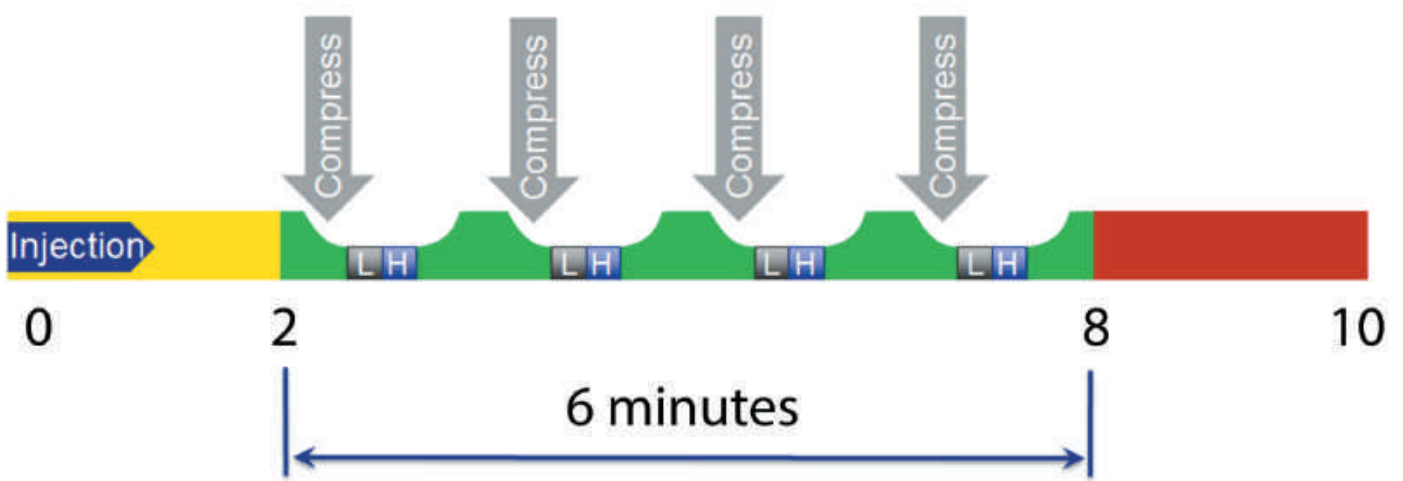


Figure 2. CE2D imaging starts approximately two minutes post injection. The breast is compressed, and then a sequence of low (L) and high (H) dual energy images are automatically acquired.

Preparing the Site

Breast clinics considering the implementation of CE mammography must be prepared to administer the contrast agent. A power injector is commonly used to deliver the bolus of contrast agent. In addition, patients will need to be assessed for renal sufficiency, and site personnel will need to determine if there is any history of reactions to contrast agents. Finally, the appropriate medical personnel and equipment needs to be available in case of adverse reactions to the contrast agent injection. These adverse reactions are quite rare, but can be severe and do occur, as with gadolinium breast MRI imaging. Guidelines for the safe use of contrast agent must be followed.

2D and 2D-Combo Contrast Imaging.

The initial investigations into contrast mammography used 2D imaging. The low and high energy imaging pairs are 2D mammograms, and the subsequent subtracted CE2D contrast image is similarly a 2D image. It has been proposed and initial studies conducted on the generation of contrast images using 3D imaging.²⁴ There may be no great advantage to obtaining a 3D contrast image over a 2D contrast image, because unlike conventional mammography where 3D is superior to 2D due to clarification of overlapping structures, there typically aren't overlapping contrast-enhancing structures in a contrast-enhanced breast image that inhibit proper image evaluation. Lesions that enhance are often small in number, and spatially distinct. However, one advantage of a 3D image over a 2D image is in the ability to localize objects in the breast.

Hologic has introduced a mode, CE2D plus 3D, that generates both the 2D contrast image and a correlated 3D non-contrast image that can be used to localize lesions seen in the CE2D image. The image examples in this paper illustrate how the CE2D combo procedure, CE2D plus 3D, gives additional information in the tomo slices that are not obtained using a standard CE2D protocol.

| Imaging Mode | 2D mammogram | 2D contrast image | 3D image |
|--------------|--------------|-------------------|----------|
| CE2D | • | • | |
| CE2D plus 3D | • | • | • |

CE2D results in both the normal mammogram and the 2D contrast image. If the combo study CE2D plus 3D is performed, there is a co-registered 3D image set in addition to the 2D images.

Radiation Dose

CE2D uses x-rays so there is radiation exposure for the procedure; however these procedures are done on symptomatic patients where radiation levels are of less concern than in screening asymptomatic women. The dual energy technique has two exposures, the low energy exposure and the high energy exposure. The high energy exposure has approximately 50% of the dose of the low energy, so a single CE2D acquisition has 1.5x the dose of the normal mammogram. If a CE2D plus 3D combo exam is performed, there is additional radiation from the 3D portion, typically 1.2x the dose of a normal 2D mammogram.

Conclusions

Contrast enhanced mammography may be a viable alternative to breast MRI in performing contrast agent breast imaging. It offers certain advantages over MRI, including reduced cost and shorter procedure times. The imaging combination of contrast enhanced 2D imaging (CE2D) along with a 3D tomo scan, gives additional information beyond a CE2D examination alone, and may allow localization and morphologic evaluation of an enhancing lesion, further increasing the value of the CE2D procedure.

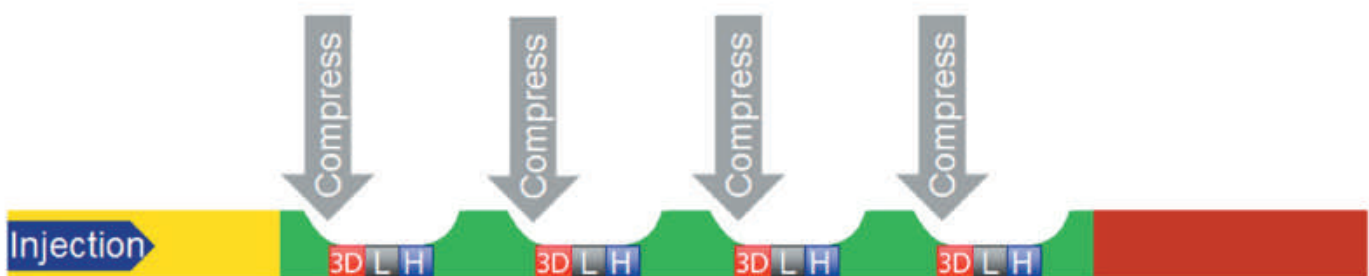


Figure 3. When CE2D is performed as part of a combo study, a tomo scan (3D) is performed along with the low (L) and high (H) 2D mammograms.

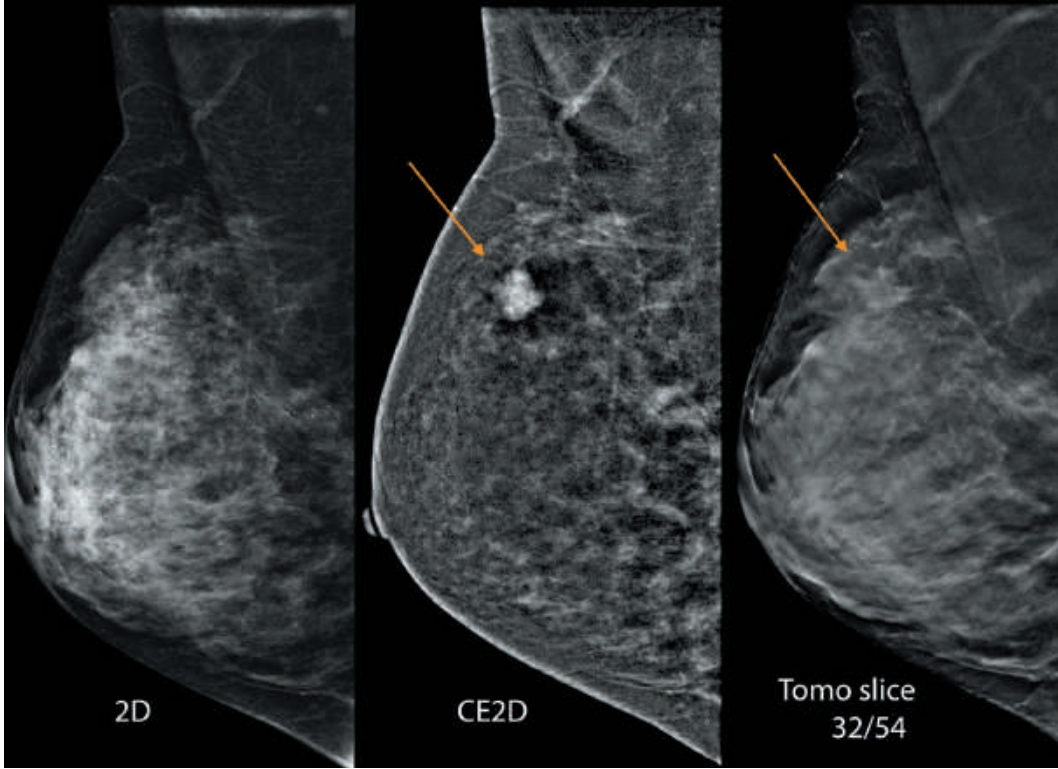


Figure 4. This heterogeneously dense breast had cancer, IDC + DCIS, which enhanced strongly on the CE2D image. Associated architectural distortion of the lesion can be seen in the tomo slice.

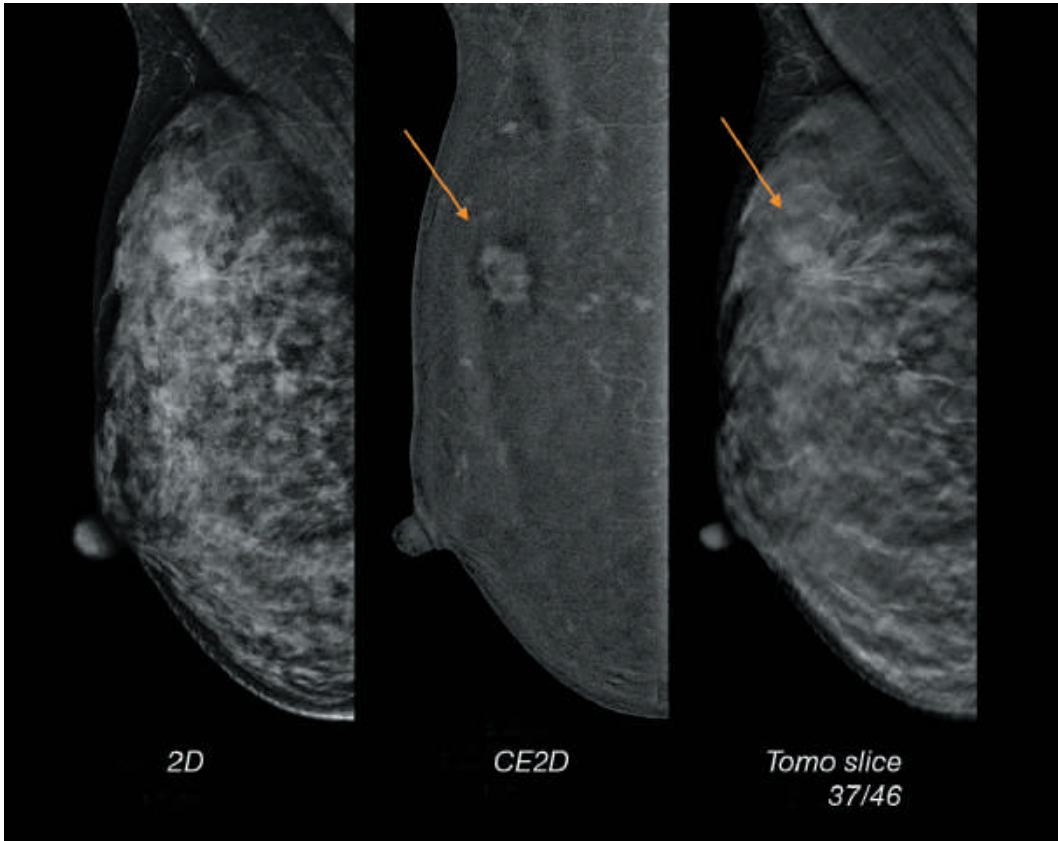


Figure 5. IDC + DCIS lesion enhanced on CE2D. The spiculations can be seen in the 2D image, but are better appreciated in the tomo slice.

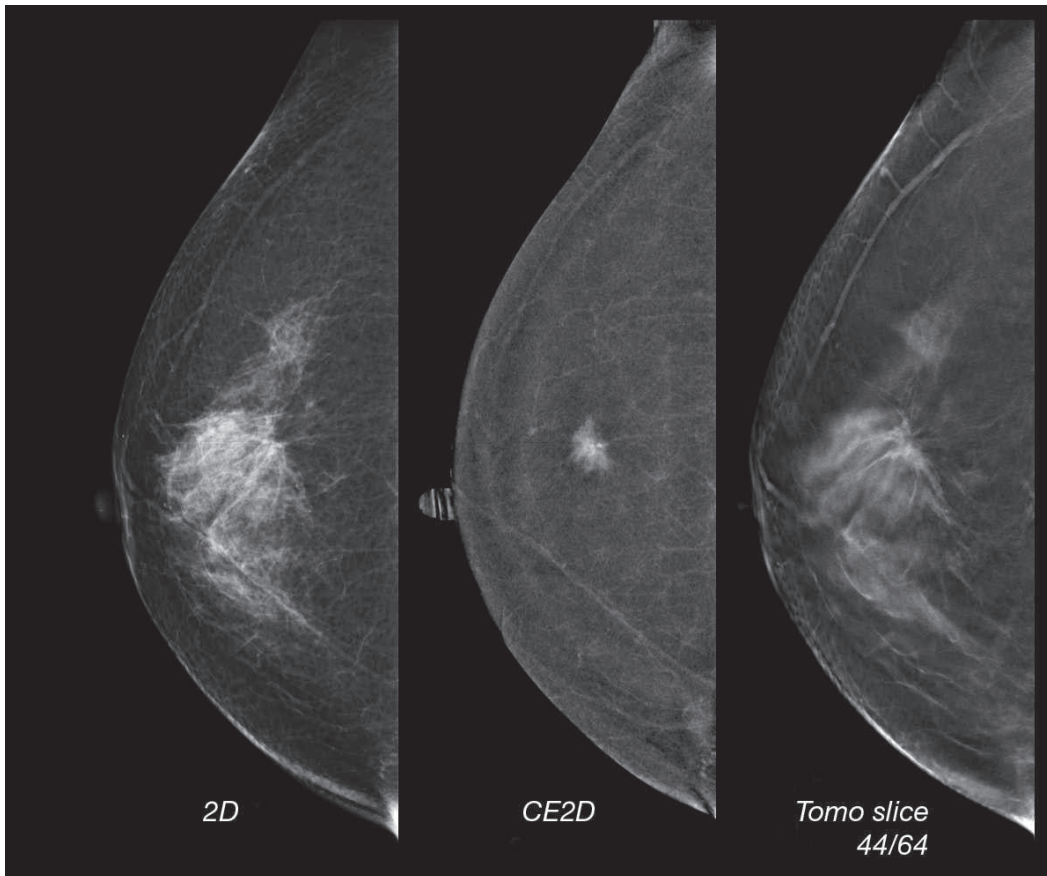


Figure 6. IDC enhances well on CE2D with spiculations seen on the tomo slice.

Glossary

| Term | Meaning |
|-------------|--|
| 2D | Digital mammography |
| 3D | Breast tomosynthesis; also known as tomo, or 3D mammography |
| CE | Contrast enhanced (imaging) |
| CE2D | Contrast enhanced 2D image |
| CE2D + 3D | Combo study with contrast enhanced 2D image and standard 3D image. |
| CT | Computed Tomography |
| DM | Digital mammography; also known as 2D |
| Gd-MRI | Gadolinium contrast-enhanced breast MRI |
| Low energy | Low kV exposure performed as part of the dual energy pair in CE2D acquisition; similar to normal mammogram |
| High energy | High kV exposure performed as part of the dual energy pair in CE2D acquisition. |
| US | Ultrasound |

References:

1. Tabar L, Vitak B, Chen HH, Yen MF, et al. Beyond randomized controlled trials: organized mammographic screening substantially reduces breast carcinoma mortality. *Cancer* 2001; 91:1724-1732
2. Tabar L, Vitak B, Chen TH, et al. Swedish two-county trial: impact of mammographic screening on breast cancer mortality during 3 decades. *Radiology* 2011; 260:658-663
3. Lehtimäki T, Lundin M, Linder N, et al. Long-term prognosis of breast cancer detected by mammography screening or other methods. *Breast Cancer Res* 2011; 13:R134
4. Friedewald SM, Rafferty EA, Rose SL, et al. Breast cancer screening using tomosynthesis in combination with digital mammography. *JAMA*, 2014 Jun 25;311(24):2499-507.
5. Narisada H(1), Aoki T, Sasaguri T, et al. Correlation between numeric gadolinium-enhanced dynamic MRI ratios and prognostic factors and histologic type of breast carcinoma. *AJR Am J Roentgenol*. 2006 Aug;187(2):297-306.
6. Chang CH, Nesbit DE, Fisher DR, et al. Computed tomographic mammography using a conventional body scanner. *American Journal of Roentgenology*, 1982;138:553-558.
7. Lewin JM, Isaacs PK, Vance V, et al. Dual-energy contrast-enhanced digital subtraction mammography: feasibility. *Radiology*. 2003 Oct;229(1):261-8.
8. Jong RA, Yaffe MJ, Skarpathiotakis M, et al. Contrast-enhanced digital mammography: initial clinical experience. *Radiology*. 2003 Sep;228(3):842-50.
9. Froeling V, Diekmann F, Renz DM, et al. Correlation of contrast agent kinetics between iodinated contrast-enhanced spectral tomosynthesis and gadolinium-enhanced MRI of breast lesions. *Eur Radiol*. 2013 Jun;23(6):1528-36.
10. Lobbes MB, Smidt ML, Houwers J, et al. Contrast enhanced mammography: techniques, current results, and potential indications. *Clin Radiol*. 2013 Sep;68(9):935-44.
11. Dromain C, Thibault F, Diekmann F, et al. Dual-energy contrast-enhanced digital mammography: initial clinical results of a multireader, multicase study. *Breast Cancer Res*. 2012 Jun 14;14(3):R94.
12. Fallenberg EM, Dromain C, Diekmann F, et al. Contrast-enhanced spectral mammography versus MRI: Initial results in the detection of breast cancer and assessment of tumour size. *Diagn Interv Imaging*. 2014 Mar;95(3):351-2.
13. Jochelson MS, Dershaw DD, Sung JS, et al. Bilateral contrast-enhanced dual-energy digital mammography: feasibility and comparison with conventional digital mammography and MR imaging in women with known breast carcinoma. *Radiology* 2013;266(3):743-51.
14. Lobbes MB, Lalji U, Houwers J, et al. Contrast-enhanced spectral mammography in patients referred from the breast cancer screening programme. *Eur Radiol*. 2014 Jul;24(7):1668-76.
15. Chen SC, Carton AK, Albert M, et al. Initial clinical experience with contrast-enhanced digital breast tomosynthesis. *Acad Radiol*. 2007 Feb;14(2):229-38.
16. Carton AK, Gavenonis SC, Currivan JA, et al. Dual-energy contrast-enhanced digital breast tomosynthesis—a feasibility study. *Br J Radiol*. 2010 Apr;83(988):344-50.
17. Chou CP, Chiang CL, Yang TL. Contrast-enhanced Breast Tomosynthesis versus Dynamic Contrast-enhanced Breast MRI in the Diagnosis of Suspicious Breast Lesions on Mammogram. Radiological Society of North America annual meeting 2013, Scientific Presentation VSB31-04.
18. *The standard mammogram (non-contrast image) visualizes microcalcifications very well, and is a standard image in an x-ray CE study.
19. Radio Contrast Agent - Available at : http://en.wikipedia.org/wiki/Radiocontrast_agent - (Accessed in 2014)
20. (a) Hunt et al. Frequency and Severity of Adverse Effects of Iodinated and Gadolinium Contrast Materials: Retrospective Review of 456,930 Doses. (b) Caro et al., The risks of death and of severe nonfatal reactions with high- vs low-osmolality contrast media: a meta-analysis. *AJR* April 1991, Volume 156, Number 4.
21. Dromain C, Thibault F, Diekmann F, et al. Dual-energy contrast-enhanced digital mammography: initial clinical results of a multireader, multicase study. *Breast Cancer Res*. 2012 Jun 14;14(3):R94.
22. Jochelson MS, Dershaw DD, Sung JS, et al. Bilateral contrast-enhanced dual-energy digital mammography: feasibility and comparison with conventional digital mammography and MR imaging in women with known breast carcinoma. *Radiology* 2013;266(3):743-51.
23. Francescone MA, Jochelson MS, Dershaw DD, et al. Low energy mammogram obtained in contrast-enhanced digital mammography (CEDM) is comparable to routine full-field digital mammography (FFDM). *Eur J Radiol*. 2014 Aug;83(8):1350-5. doi: 10.1016/j.ejrad.2014.05.015.
24. Dual-energy Contrast-enhanced (2D and 3D Mammography Versus Contrast-enhanced MRI)- A Pilot Study (Hologic). - Available at: <http://clinicaltrials.gov/show/NCT01433640> - (Accessed in 2014)

Hologic BV
Da Vincilaan 5,
1935 Zaventem
Tel: +32.2.711.4680
info@hologic.com
www.hologic.com